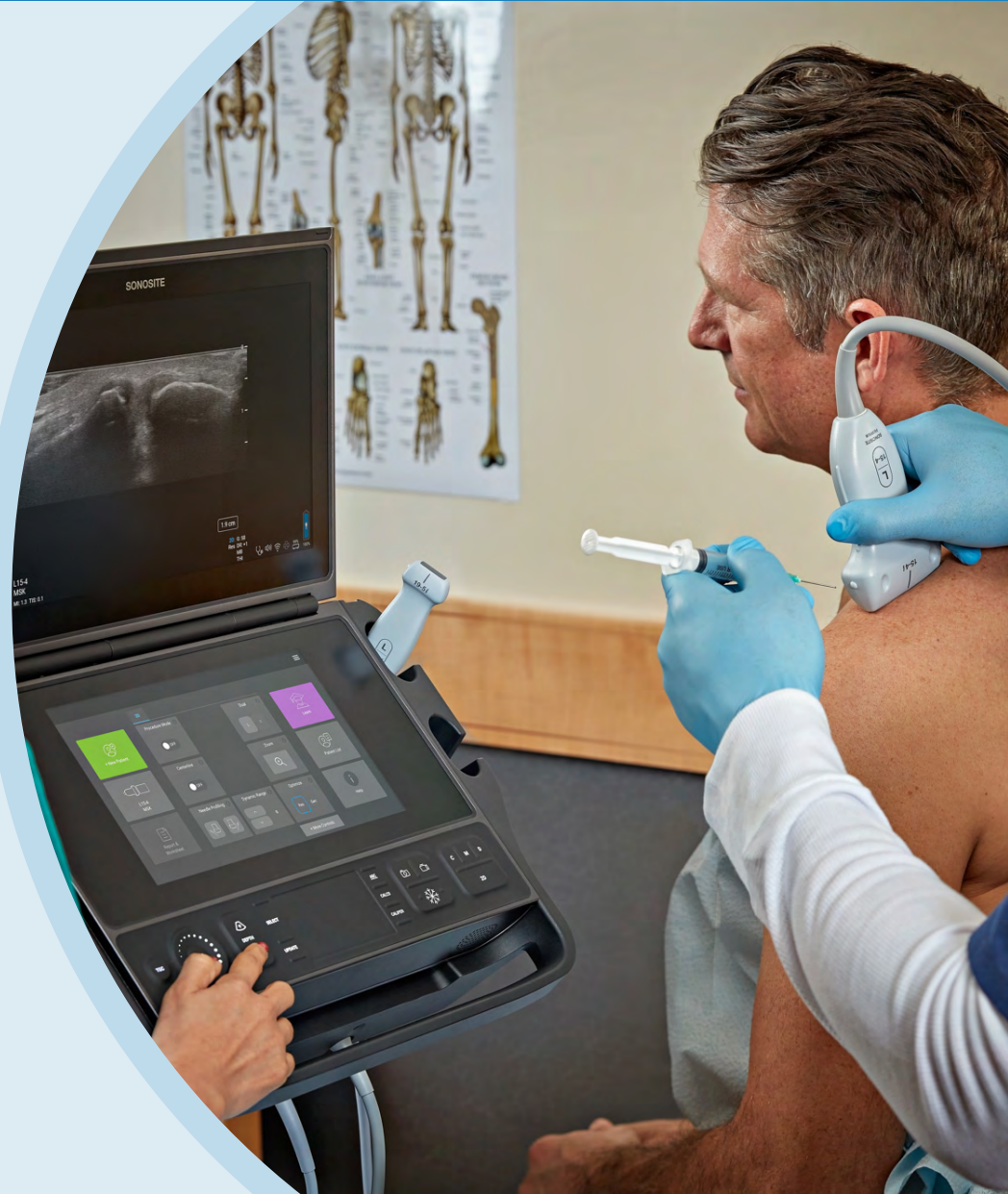

Musculoskeletal Quick Guide

Any patient. Anywhere. Anytime.



BICEPS TENDON LONG HEAD

Objective:

Image the Biceps Tendon (BT) to evaluate for longitudinal split tears, fluid within the sheath, dislocation, or subluxation.

The BT long head of the shoulder can be easily scanned using ultrasound to diagnose longitudinal and partial tears, tendinitis, tendinosis, fluid in the tendon sheath, and total ruptures. Tendon sheath injections and needling procedures of the tendon can also be performed utilizing ultrasound-guidance.

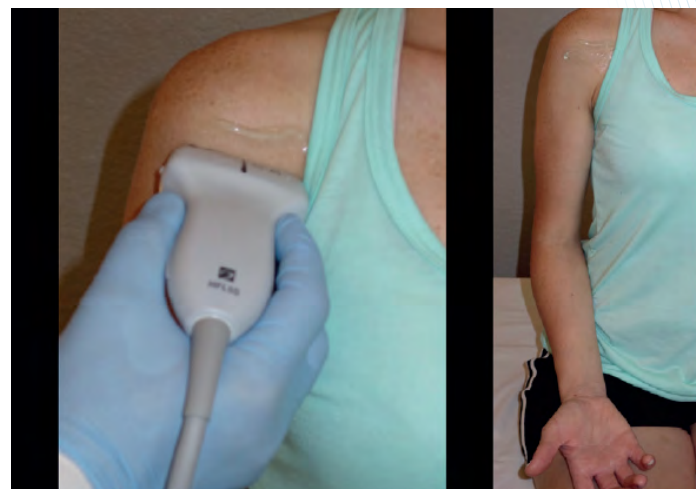
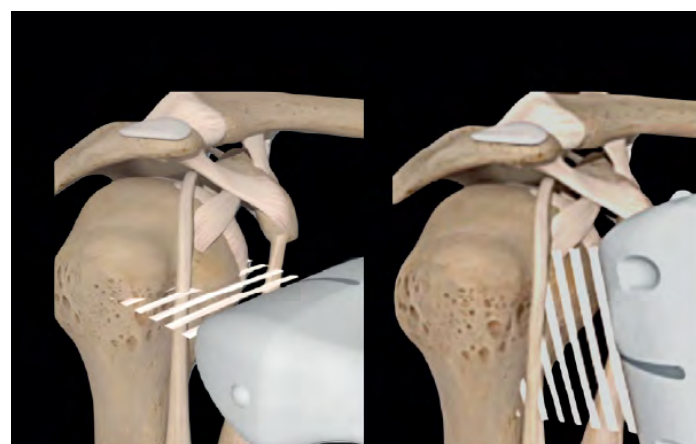


Fig. 1



Transverse Transducer Position

Longitudinal Transducer Position

Fig. 2

Any patient. Anywhere. Anytime.

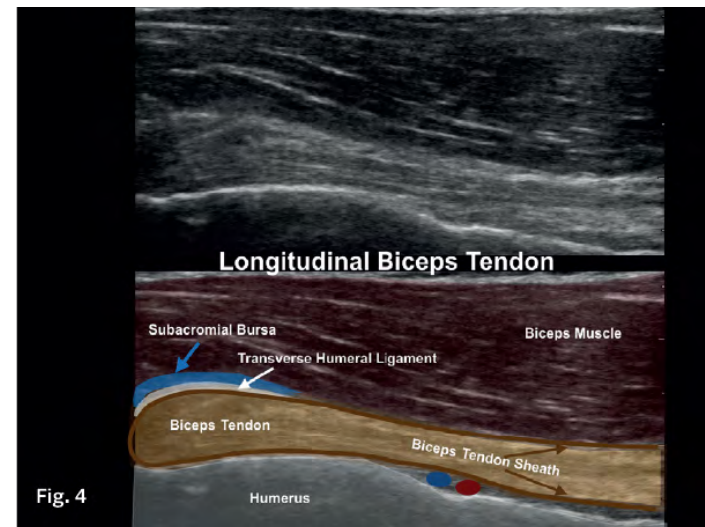
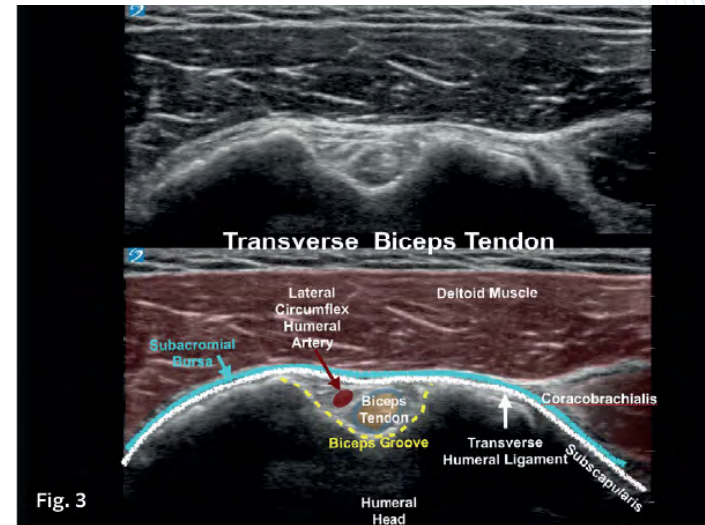
This Quick Guide is intended for healthcare professionals and not for patients or consumers. The information in this Quick Guide is provided for general educational purposes, as a convenient quick reference and a supplement to professional experience, education and training, and should not be considered the exclusive source for this type of information. This Quick Guide does not replace or supersede device labeling, including instructions for use, which accompanies any FUJIFILM Sonosite product. At all times, it is the professional responsibility of the practitioner to exercise independent clinical judgment in each particular situation. FUJIFILM Sonosite assumes no responsibility or liability for any misuse of this Quick Guide. SONOSITE and the SONOSITE logo are trademarks and registered trademarks of FUJIFILM Sonosite, Inc. in various jurisdictions. FUJIFILM is a trademark and registered trademark of FUJIFILM Corporation in various jurisdictions. All other trademarks are the property of their respective owners.

Biceps tendon long head

The Biceps Tendon (BT) originates within the Glenohumeral (GH) joint of the biceps tubercle on the superior part of the GH labrum. It is enveloped by a tendon sheath, which is an extension of the synovial membrane of the GH joint. This sheath extends to about 3-4 cm distal to the biceps groove. As the tendon and its sheath enter the biceps groove, they are covered by the relatively weak transverse humeral ligament, which is the hyperechoic layer immediately superficial to the BT sheath.

Clinical Pearls:

- Patient Positioning: The patient should be seated with the elbow flexed 90 degrees, and the patient's ipsilateral hand should be placed supinated and resting on the anterior thigh. (Fig. 1)
- Transducer: Use a high frequency linear transducer and the MSK exam type setting at a depth of 2-3 cm.
- Transducer Position: Place the transducer in the short axis at the level of the coracoid process of the upper arm to scan the BT in its short axis. (Fig. 2)
- Scan the BT distally in the short axis. The groove will start to flatten, and the pectoralis major tendon will begin to appear as it attaches to the humerus. The pectoralis major tendon lies superficial to the BT long head, while the BT short head and coracobrachialis muscles lie immediately medial to the BT long head. (Fig. 3)
- Return to the proximal biceps groove, and rotate the transducer sagittally along the tendon for a longitudinal midline image of the long head of the BT. Image the BT slowly from the superior aspect of the humeral head to the myotendinous junction of the BT long head distally. (Fig. 4)
- The ascending branch of the circumflex humeral artery may be seen running along the lateral wall of the proximal biceps groove before it dives medial-to-lateral beneath the BT more distally. This may be confirmed using color Doppler.
- The BT is subject to anisotropic artifact. Adjust the transducer to offset anisotropy by heel-toeing the transducer to maintain a uniform image of the BT.



Any patient. Anywhere. Anytime.

This Quick Guide is intended for healthcare professionals and not for patients or consumers. The information in this Quick Guide is provided for general educational purposes, as a convenient quick reference and a supplement to professional experience, education and training, and should not be considered the exclusive source for this type of information. This Quick Guide does not replace or supersede device labeling, including instructions for use, which accompanies any FUJIFILM Sonosite product. At all times, it is the professional responsibility of the practitioner to exercise independent clinical judgment in each particular situation. FUJIFILM Sonosite assumes no responsibility or liability for any misuse of this Quick Guide. SONOSITE and the SONOSITE logo are trademarks and registered trademarks of FUJIFILM Sonosite, Inc. in various jurisdictions. FUJIFILM is a trademark and registered trademark of FUJIFILM Corporation in various jurisdictions. All other trademarks are the property of their respective owners.

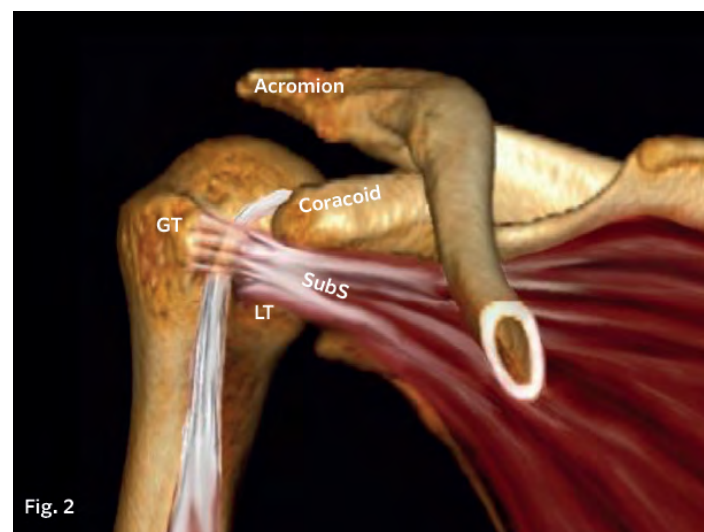
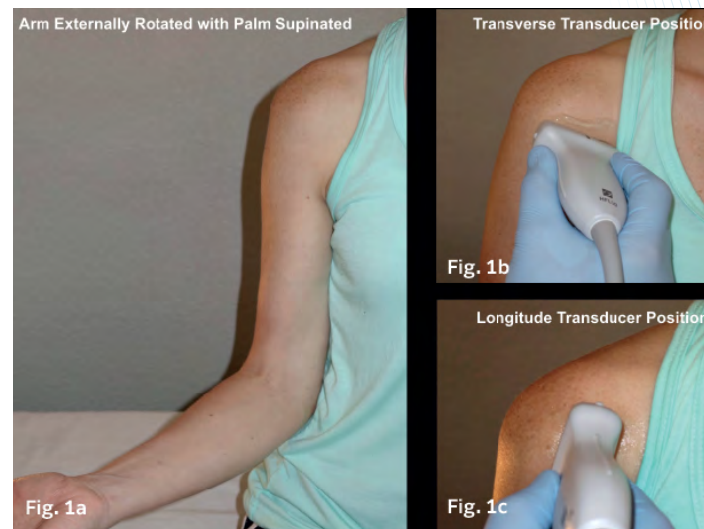
SUBSCAPULARIS MUSCLE AND TENDON

Objective:

Image the Subscapularis (SubS) muscle and tendon in both the longitudinal and transverse planes.

The SubS muscle and tendon origin is comprised of three separate parallel muscle bundles with each terminating in its own myotendinous junction. The superior edge of the myotendinous portion of the SubS is at the level of the coracoid process.

Longitudinal tears, partial tears, tendinosis, fluid in the subdeltoid bursa, and total ruptures can be easily seen with ultrasound. Accurate ultrasound-guided tendon regenerative injections and needling procedures of the tendon can be performed.



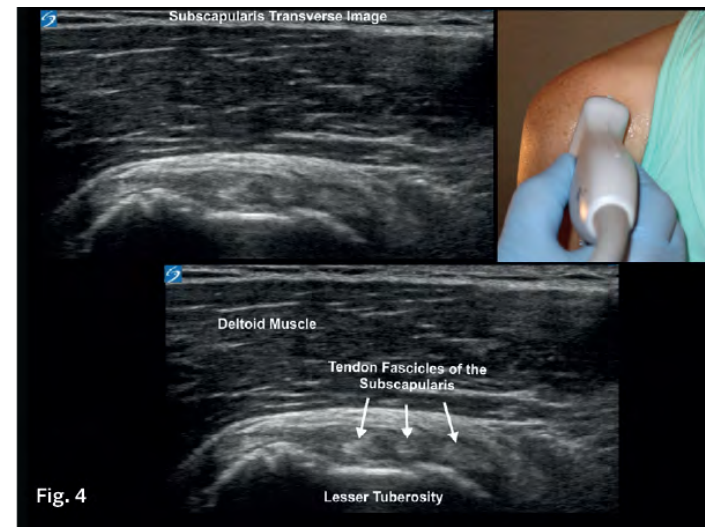
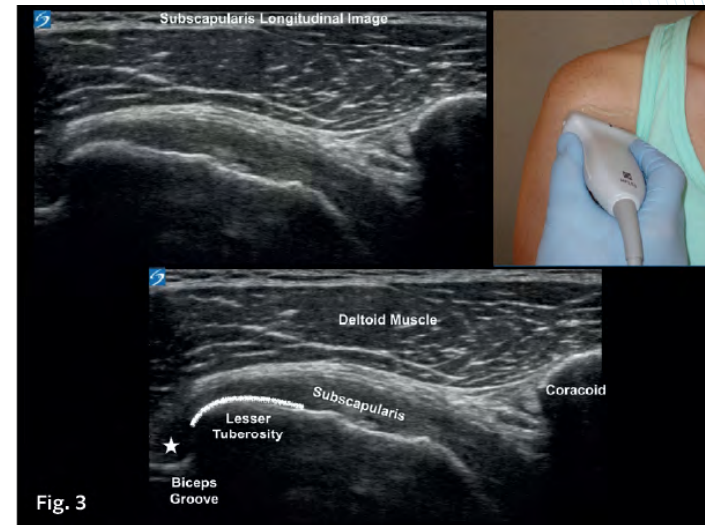
Any patient. Anywhere. Anytime.

This Quick Guide is intended for healthcare professionals and not for patients or consumers. The information in this Quick Guide is provided for general educational purposes, as a convenient quick reference and a supplement to professional experience, education and training, and should not be considered the exclusive source for this type of information. This Quick Guide does not replace or supersede device labeling, including instructions for use, which accompanies any FUJIFILM Sonosite product. At all times, it is the professional responsibility of the practitioner to exercise independent clinical judgment in each particular situation. FUJIFILM Sonosite assumes no responsibility or liability for any misuse of this Quick Guide. SONOSITE and the SONOSITE logo are trademarks and registered trademarks of FUJIFILM Sonosite, Inc. in various jurisdictions. FUJIFILM is a trademark and registered trademark of FUJIFILM Corporation in various jurisdictions. All other trademarks are the property of their respective owners.

Subscapularis muscle and tendon

Clinical Pearls:

- **Patient Positioning:** The patient should be seated with the arm externally rotated and the palm supinated. (Fig. 1a)
- **Transducer:** Use a high frequency linear transducer and the MSK exam type at a depth of 2-3 cm.
- **Transducer Position:** Palpate the coracoid process, and place the transducer in the transverse plane at the level of the inferior edge of the coracoid over the medial humerus as in Fig. 1b.
- The SubS appears as a bird's beak shape over the medial surface of the lesser tuberosity in the longitudinal image of the SubS. (Fig. 3)
- Scan the entire width of the tendon moving the transducer from superior-to-inferior.
- Bright hyperechoic deposits are often seen in middle-aged and older patients, because the SubS is the most commonly calcified tendon in the rotator cuff.
- Fix the transducer on the skin, and ask the patient to rotate from internal rotation to external rotation as you watch. Evaluate the clearance of the lesser tuberosity as it slides deep to the lateral edge of the coracoid.
- Rotate the transducer 90 degrees around its midpoint to look at the SubS myotendinous junction in its short axis. (Fig. 1c)
- Direct the beam a bit towards LATERAL to see the heterogeneous appearance of the SubS in the transverse image.
- There are three separate myotendinous junctions where each of the three isoechoic tendons is surrounded by its hypoechoic muscle fibers, which creates a heterogeneous affect. (Fig. 4).
- Do not mistake these hypoechoic areas for tears in the SubS tendon.



Any patient. Anywhere. Anytime.

This Quick Guide is intended for healthcare professionals and not for patients or consumers. The information in this Quick Guide is provided for general educational purposes, as a convenient quick reference and a supplement to professional experience, education and training, and should not be considered the exclusive source for this type of information. This Quick Guide does not replace or supersede device labeling, including instructions for use, which accompanies any FUJIFILM Sonosite product. At all times, it is the professional responsibility of the practitioner to exercise independent clinical judgment in each particular situation. FUJIFILM Sonosite assumes no responsibility or liability for any misuse of this Quick Guide. SONOSITE and the SONOSITE logo are trademarks and registered trademarks of FUJIFILM Sonosite, Inc. in various jurisdictions. FUJIFILM is a trademark and registered trademark of FUJIFILM Corporation in various jurisdictions. All other trademarks are the property of their respective owners.

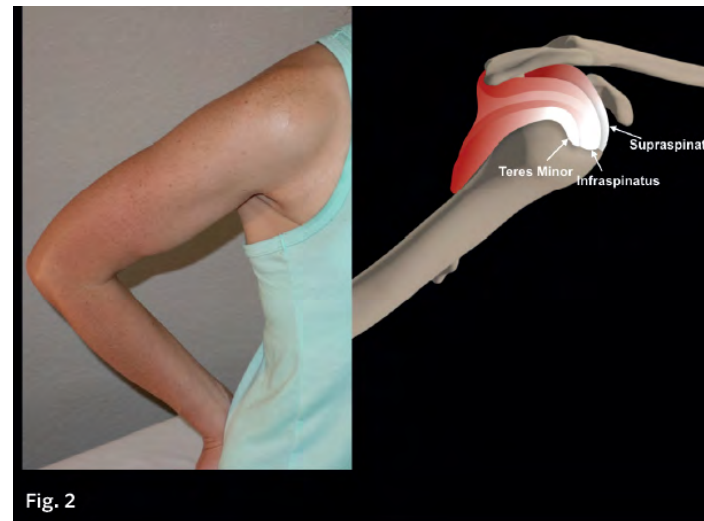
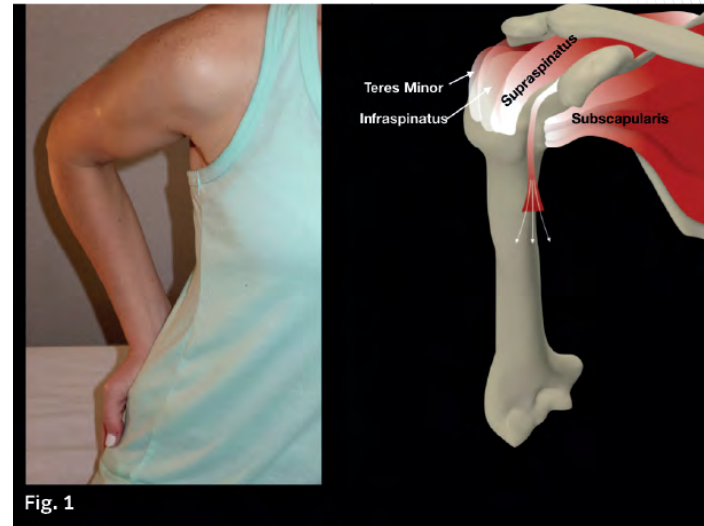
SHOULDER: SUPRASPINATUS TENDON

Objective:

Diagnostically image the Supraspinatus Tendon (SST), and differentiate it from the surrounding infraspinatus tendon and rotator cuff interval structures.

The SST is the main tendon of the four rotator cuff tendons and is responsible for abduction. The supraspinatus muscle originates on the superior surface of the scapula and is called the supraspinatus fossa. The supraspinatus muscle extends laterally and inserts on the anterior facet of the Greater Tuberosity (GT).

The insertion of the SST extends slightly posterior into about 1/3 of the middle facet of the GT. The undersurface of the SST also has some fibers that extend from the coracohumeral ligament (see the rotator cuff interval quick guide). The most commonly torn tendon in the rotator cuff is the SST at its anterior margin as it borders the biceps tendon within the interval.



Any patient. Anywhere. Anytime.

This Quick Guide is intended for healthcare professionals and not for patients or consumers. The information in this Quick Guide is provided for general educational purposes, as a convenient quick reference and a supplement to professional experience, education and training, and should not be considered the exclusive source for this type of information. This Quick Guide does not replace or supersede device labeling, including instructions for use, which accompanies any FUJIFILM Sonosite product. At all times, it is the professional responsibility of the practitioner to exercise independent clinical judgment in each particular situation. FUJIFILM Sonosite assumes no responsibility or liability for any misuse of this Quick Guide. SONOSITE and the SONOSITE logo are trademarks and registered trademarks of FUJIFILM Sonosite, Inc. in various jurisdictions. FUJIFILM is a trademark and registered trademark of FUJIFILM Corporation in various jurisdictions. All other trademarks are the property of their respective owners.

Shoulder: Supraspinatus tendon

The Supraspinatus Tendon (SST) is a highly mobile rotator cuff tendon that inserts on the Greater Tuberosity (GT). Proper patient positioning is critical to perform reliable and accurate examinations. For example, anatomy books will show the SST as a laterally located tendon, because they all depict anatomy from the anatomical position. This means the shoulder is in external rotation with the palm facing forward, and the arm is slightly abducted away from the body. The SST is not well visualized in the anatomical position, because the acromion process of the scapula will overshadow the bulk of the SST. The arm must be positioned in a way that delivers the SST out from beneath the acromion process to completely evaluate the SST.

Clinical Pearls:

- **Patient Positioning:** Position the shoulder into an internal rotation with the elbow bent 90 degrees and the hand placed on the patient's hip or back pocket. This is called the "modified Crass position." (Fig. 1 and Fig. 2)
- Position the elbow toward the patient's spine. If the elbow relaxes away from the body, internal over-rotation will occur, which sends the rotator cuff structures underneath the coracoid process.
- **Transducer:** Use a high frequency linear transducer and the MSK exam type setting at a depth of 2-4 cm.
- **Transverse Scan:** Place the transducer just anterior to the acromion process, and slightly laterally direct it toward the xyphoid process. (Fig. 3).
- **Longitudinal Scan:** Rotate the transducer 90 degrees to the transverse scan. Take care to avoid anisotropic artifact at the SST insertion. (Fig. 4)
 - The beam should be perpendicular to the humeral head and not the patient's skin.
 - Scan laterally until the enthesis of the SST is seen at the GT anterior middle facets. (Fig. 3c)
 - Posteriorly, the SST footprint flattens out as it merges with the infraspinatus (Fig. 4c), and the tendon will interdigitate with anisotropic echoes.
 - The more anterior the SST footprint, the more curved the GT becomes (Fig. 4b) before dropping off to the rotator cuff interval that contains the biceps tendon long head, which is parallel to the SST. (Fig. 4a)

Transducer Position:

Any patient. Anywhere. Anytime.

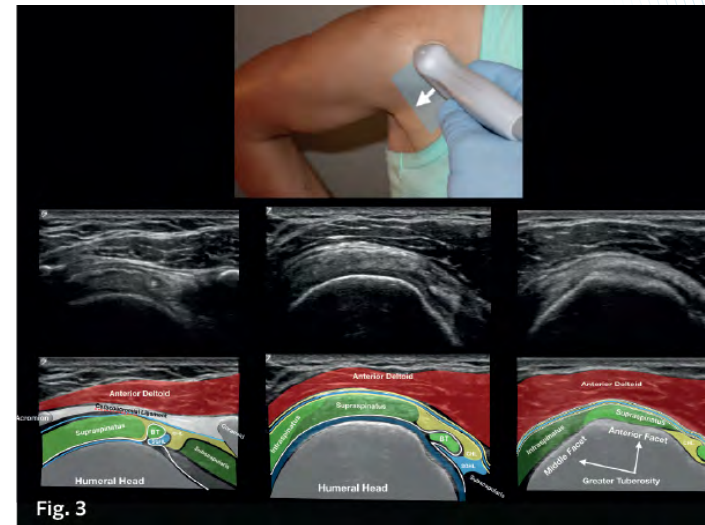


Fig. 3

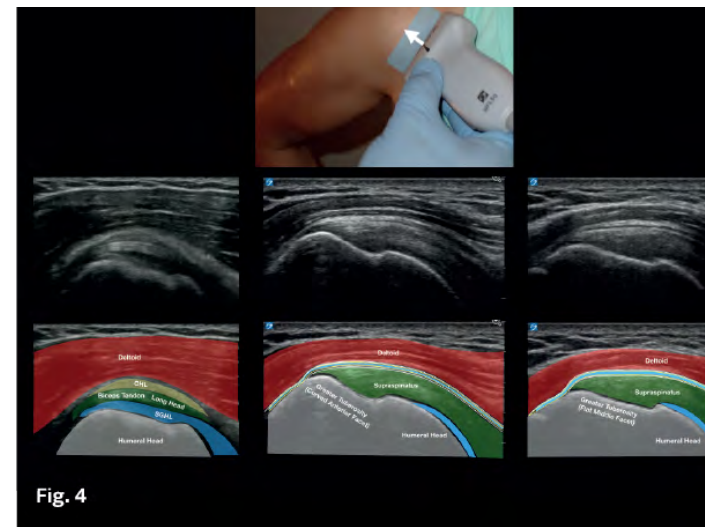


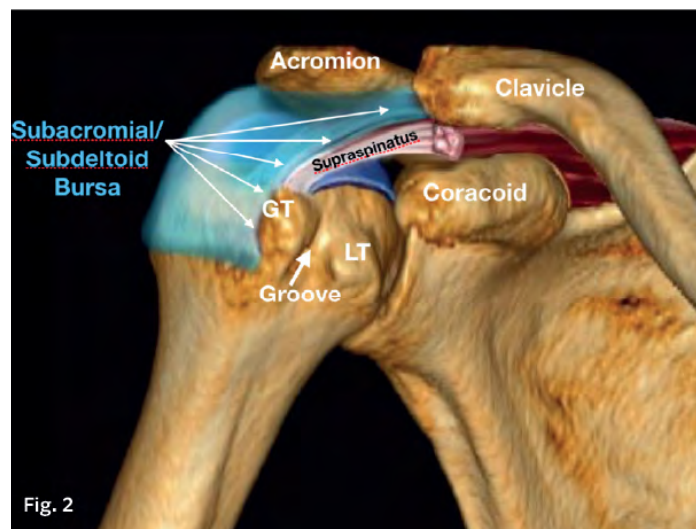
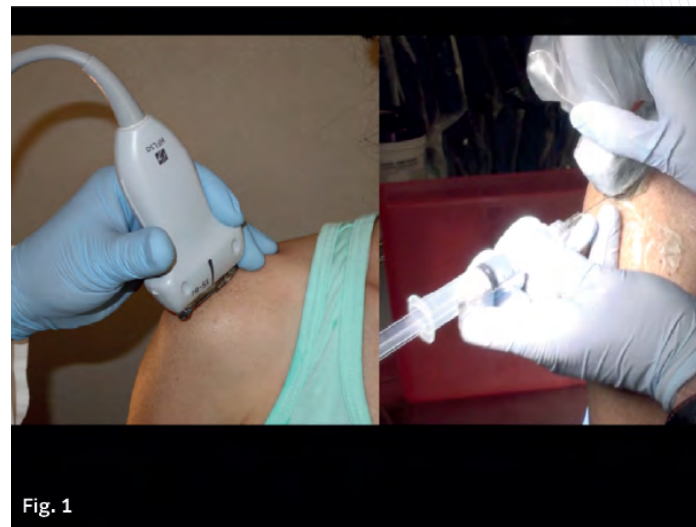Fig. 4

SHOULDER: SUBACROMIAL-SUBDELTOID BURSA INJECTION

Objective:

Place the needle within the interface of the Subacromial-Subdeltoid (SASD) bursa. The easiest approach with using ultrasound to inject this bursa is on the anterolateral aspect of the shoulder with the needle traveling from distal-to-proximal through the deltoid muscle and its fat pad into the bursa. Proper placement of the injectate results in immediate symptom relief, which is usually accompanied by an immediate increase in shoulder range of motion.

The bursa responsible for smooth gliding of the rotator cuff under the acromion process is called the subacromial bursa. However, when this bursa traverses under the deltoid muscle laterally, the name changes to subdeltoid bursa. The combined name, "Subacromial/Subdeltoid," (SASD) bursa is commonly used. The bursa becomes inflamed by over-use, scarring, or an irregularity of the undersurface of the acromion process in the shape of a hook, which can impede normal motion of the rotator cuff and cause impingement or tearing in the rotator cuff over time.



Any patient. Anywhere. Anytime.

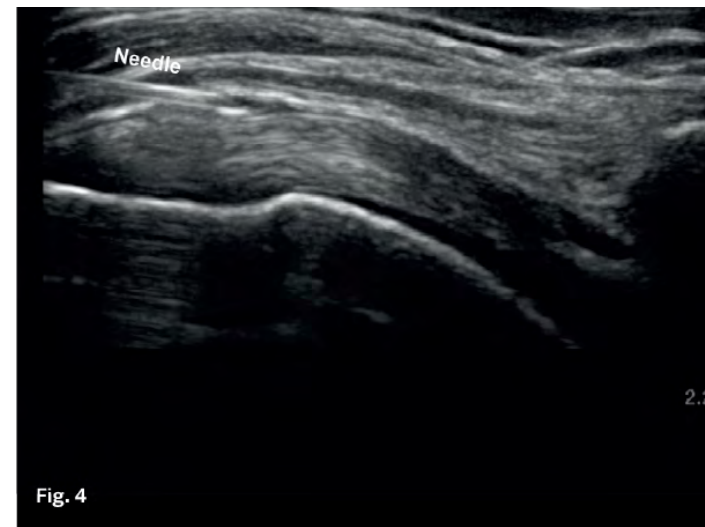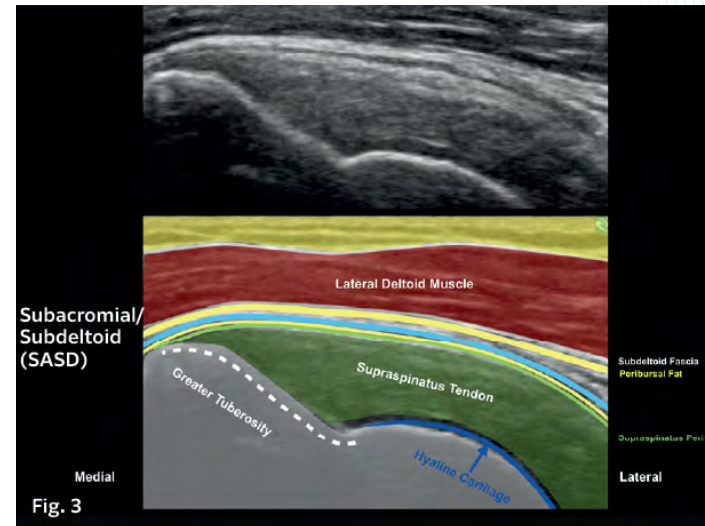
This Quick Guide is intended for healthcare professionals and not for patients or consumers. The information in this Quick Guide is provided for general educational purposes, as a convenient quick reference and a supplement to professional experience, education and training, and should not be considered the exclusive source for this type of information. This Quick Guide does not replace or supersede device labeling, including instructions for use, which accompanies any FUJIFILM Sonosite product. At all times, it is the professional responsibility of the practitioner to exercise independent clinical judgment in each particular situation. FUJIFILM Sonosite assumes no responsibility or liability for any misuse of this Quick Guide. SONOSITE and the SONOSITE logo are trademarks and registered trademarks of FUJIFILM Sonosite, Inc. in various jurisdictions. FUJIFILM is a trademark and registered trademark of FUJIFILM Corporation in various jurisdictions. All other trademarks are the property of their respective owners.

Shoulder: Subacromial-subdeltoid bursa injection

Injection of the Subacromial Subdeltoid (SASD) bursa is a commonly performed procedure. When done blind, the injection usually misses the bursa. This large bursa covers much of the shoulder joint and lies between the adjacent and hyperechoic fat pads of the deltoid and rotator cuff tendons. The fat pads are easily visible, but the bursa is often not well seen on ultrasound, because most of it is a potential space. Unless the bursa contains fluid, it is invisible to ultrasound.

Clinical Pearls:

- Patient Positioning: Place the patient in a contralateral decubitus position with the affected shoulder facing up.
- Imaging of the entire supraspinatus/infraspinatus tendons is not needed for this injection.
- 1/3 of the transducer can be placed on the acromion, which will also help avoid transducer drift.
- Partial transducer placement on the edge of the acromion process will also help avoid compression of the potential space.
- Transducer: Use a high frequency linear transducer with the MSK exam type setting at a depth of 2-3 cm.
- Needle entry: Insert the needle 1 cm from the transducer surface in the long axis. Advance the needle BEVEL UP, and direct the needle to just on top and parallel to the rotator cuff bursal surface fibers.
- If the interface of the bursa and rotator cuff is not easily seen, small passive rotations of the shoulder will help delineate the more mobile rotator cuff from the relatively stationary deltoid muscle.
- Injectate should not build up around the needle. Instead, the bursal interface should remain relatively flat during the injection because of its spread throughout the potential space of the SASD.



Any patient. Anywhere. Anytime.

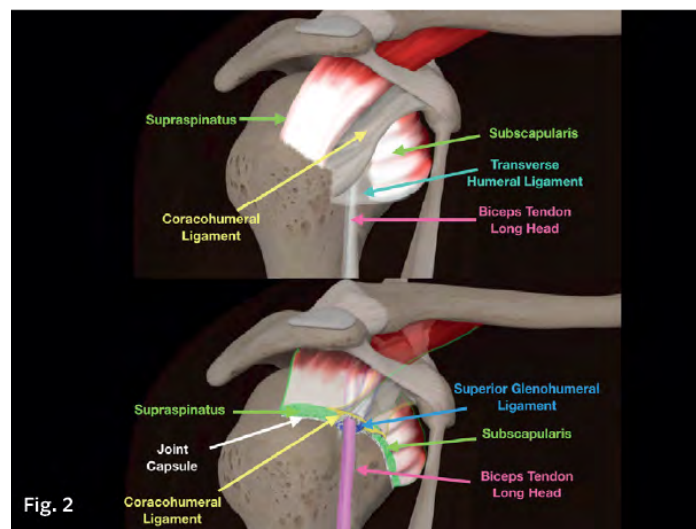
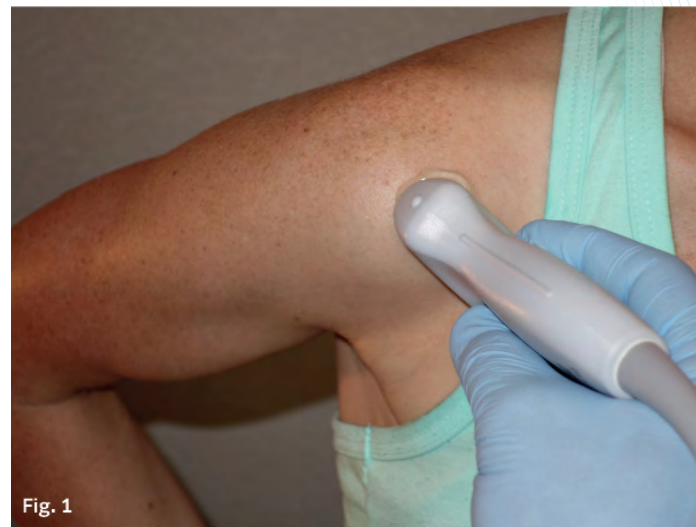This Quick Guide is intended for healthcare professionals and not for patients or consumers. The information in this Quick Guide is provided for general educational purposes, as a convenient quick reference and a supplement to professional experience, education and training, and should not be considered the exclusive source for this type of information. This Quick Guide does not replace or supersede device labeling, including instructions for use, which accompanies any FUJIFILM Sonosite product. At all times, it is the professional responsibility of the practitioner to exercise independent clinical judgment in each particular situation. FUJIFILM Sonosite assumes no responsibility or liability for any misuse of this Quick Guide. SONOSITE and the SONOSITE logo are trademarks and registered trademarks of FUJIFILM Sonosite, Inc. in various jurisdictions. FUJIFILM is a trademark and registered trademark of FUJIFILM Corporation in various jurisdictions. All other trademarks are the property of their respective owners.

SHOULDER: ROTATOR CUFF INTERVAL

Objective:

Identify and evaluate the tendons and ligaments of the rotator cuff interval.

Shoulder ultrasound of the rotator cuff interval is performed to assist in the diagnosis of biceps tendon instability, glenohumeral joint instability, and adhesive capsulitis. Ultrasound has been proven to have the same specificity and sensitivity as MRI for the evaluation of rotator cuff tears.



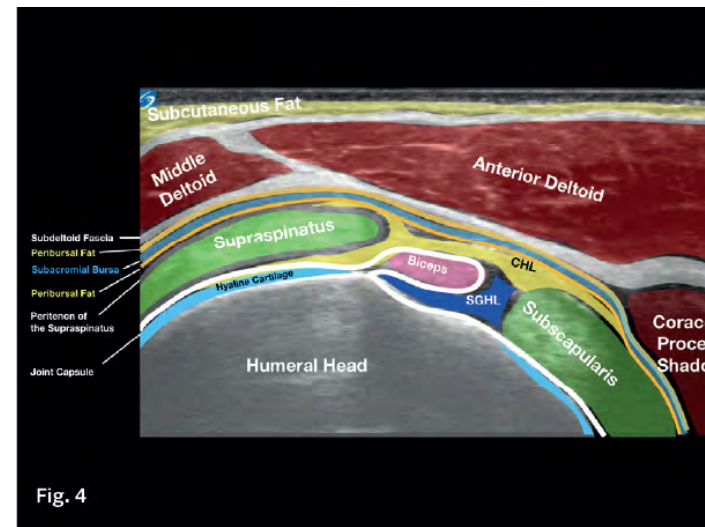
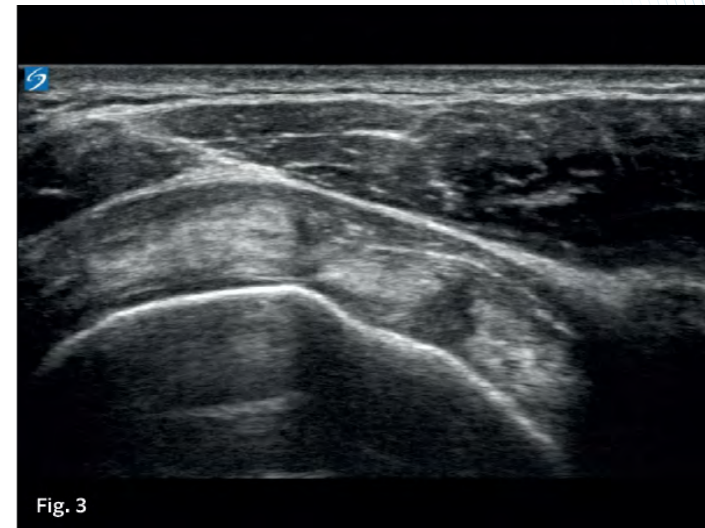
Any patient. Anywhere. Anytime.

This Quick Guide is intended for healthcare professionals and not for patients or consumers. The information in this Quick Guide is provided for general educational purposes, as a convenient quick reference and a supplement to professional experience, education and training, and should not be considered the exclusive source for this type of information. This Quick Guide does not replace or supersede device labeling, including instructions for use, which accompanies any FUJIFILM Sonosite product. At all times, it is the professional responsibility of the practitioner to exercise independent clinical judgment in each particular situation. FUJIFILM Sonosite assumes no responsibility or liability for any misuse of this Quick Guide. SONOSITE and the SONOSITE logo are trademarks and registered trademarks of FUJIFILM Sonosite, Inc. in various jurisdictions. FUJIFILM is a trademark and registered trademark of FUJIFILM Corporation in various jurisdictions. All other trademarks are the property of their respective owners.

Shoulder: Rotator cuff interval

Clinical Pearls:

- Patient Positioning: Place the arm at the patient's side with a slight external rotation, or place the patient in a modified Crass position. (Fig. 1)
- Transducer: Use a high frequency linear transducer and the MSK exam type setting at a depth of 2-3 cm.
- Transducer Position: Resting on front lateral edge of the acromion process, direct the transducer toward the umbilicus and 90 degrees to the surface of the humerus (not the skin). (Fig. 1)
- Do not use too much pressure, as this will collapse the subacromial bursa and other useful pathologies in the area.
- The Anatomy of the Rotator Cuff Interval. Fig 2 and Fig 4
 - Superior Glenohumeral Ligament (SGHL)
 - Biceps Long (BL) head
 - Coracohumeral Ligament (CHL)
 - Supraspinatus (SSp)
 - Subscapularis (SSc)
- The short axis view of the SSc, BL, and SSp can all be captured simultaneously, and this is called the "interval view." (Fig. 3)
- To view the SSp in its long axis, place the transducer over the tendon and rotate 90 degrees for the longitudinal view of the humeral head-neck junction to see the "interval view." (Fig. 3)
- The most medial structure should be the SSc. The CHL and the SGHL are also visible; they form the reflection pulley preventing medial subluxation of the biceps tendon.



Any patient. Anywhere. Anytime.

This Quick Guide is intended for healthcare professionals and not for patients or consumers. The information in this Quick Guide is provided for general educational purposes, as a convenient quick reference and a supplement to professional experience, education and training, and should not be considered the exclusive source for this type of information. This Quick Guide does not replace or supersede device labeling, including instructions for use, which accompanies any FUJIFILM Sonosite product. At all times, it is the professional responsibility of the practitioner to exercise independent clinical judgment in each particular situation. FUJIFILM Sonosite assumes no responsibility or liability for any misuse of this Quick Guide. SONOSITE and the SONOSITE logo are trademarks and registered trademarks of FUJIFILM Sonosite, Inc. in various jurisdictions. FUJIFILM is a trademark and registered trademark of FUJIFILM Corporation in various jurisdictions. All other trademarks are the property of their respective owners.

Shoulder: Infrapinatus Tendon

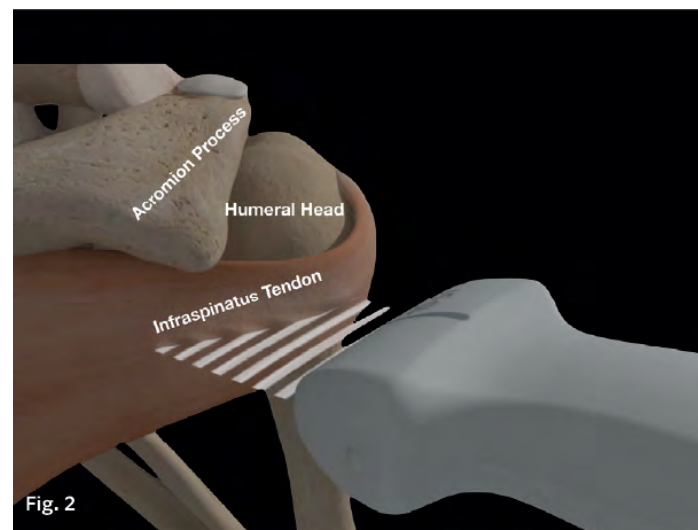
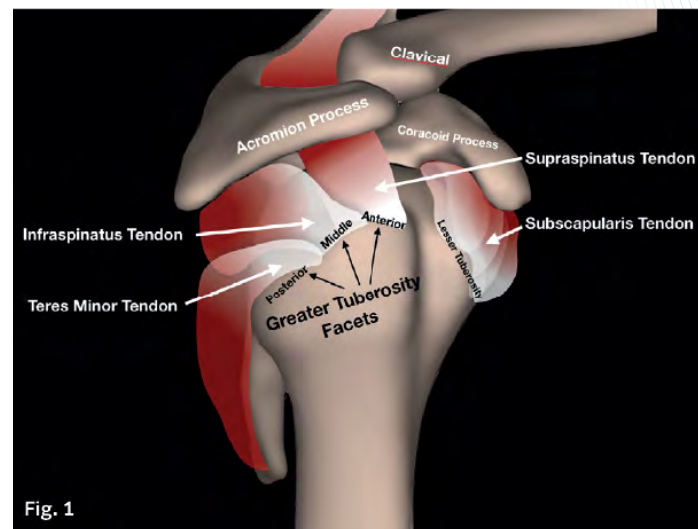
Objective:

Diagnostically image the infrapinatus tendon, and differentiate it from the surrounding suprapinatus and teres minor tendon insertions.

The infrapinatus tendon is one of the four rotator cuff tendons; specifically, it is a posterior external rotator. The infrapinatus muscle originates as a large multipennate muscle over the upper 2/3 of the scapula's posterior surface. It extends laterally over the glenohumeral joint in a horizontal fashion and inserts on the middle facet of the greater tuberosity. (Fig. 1)

The insertion actually extends slightly over the more superior and anterior suprapinatus tendon and shares 1/3 of its footprint at the apex of the greater tuberosity. Localized infrapinatus tendon tears are rare and typically share partial involvement with the suprapinatus tendon due, in part, to this overlapping architecture of the so-called "suprapinatus/infrapinatus junction."

The infrapinatus tendon is very long relative to other tendons of the shoulder. It originates at the body of the scapula and inserts on the middle facet of the greater tuberosity, as previously stated. Because of this tendon's long course and insertion point on the highly mobile humeral head, patient positioning and proper transducer placement are critical in order to evaluate the infrapinatus tendon properly.



Any patient. Anywhere. Anytime.

This Quick Guide is intended for healthcare professionals and not for patients or consumers. The information in this Quick Guide is provided for general educational purposes, as a convenient quick reference and a supplement to professional experience, education and training, and should not be considered the exclusive source for this type of information. This Quick Guide does not replace or supersede device labeling, including instructions for use, which accompanies any FUJIFILM Sonosite product. At all times, it is the professional responsibility of the practitioner to exercise independent clinical judgment in each particular situation. FUJIFILM Sonosite assumes no responsibility or liability for any misuse of this Quick Guide. SONOSITE and the SONOSITE logo are trademarks and registered trademarks of FUJIFILM Sonosite, Inc. in various jurisdictions. FUJIFILM is a trademark and registered trademark of FUJIFILM Corporation in various jurisdictions. All other trademarks are the property of their respective owners.

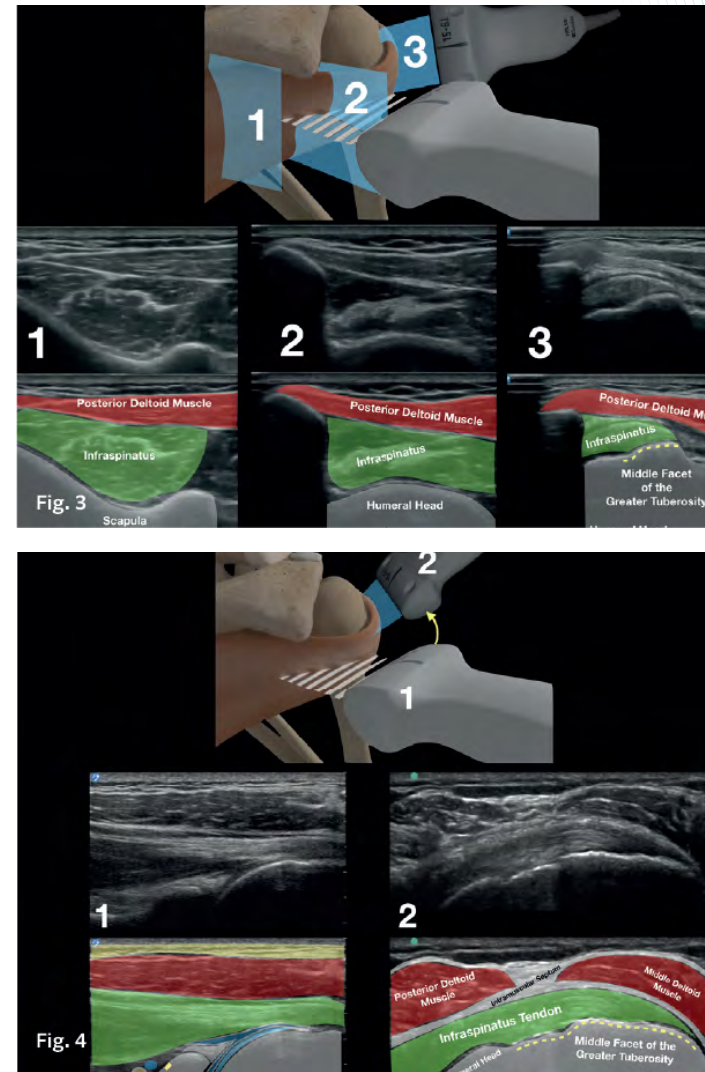
Shoulder: Infrapinatus tendon

Clinical Pearls:

- **Patient Positioning:** Internally rotate the patient's arm, and rest the palm on the abdomen with the elbow close to the body. This will bring the infrapinatus tendon into a taut position, and deliver it from its normal posterior location (anatomical position) to an anterolateral position because of the internally rotated humeral head.
 - direct it slightly downward towards the glenohumeral joint. (Fig. 4)
 - This will allow you to visualize the main body of the infrapinatus tendon.
 - Follow it laterally, and maintain a 90 degree angle of incidence to the humeral head.
 - Eventually, end the longitudinal scan of the infrapinatus laterally on the humeral head as the infrapinatus tapers to a point on the middle facet of the greater tuberosity while maintaining a relative axial body plane. (Fig. 4, position 2)
- **Transducer:** Use a high frequency linear transducer and the MSK exam type setting at a depth of 2-4 cm.

Transducer Position:

- **Transverse Scan:**
 - Proximally, follow the scapular spine with the transducer, and rest the upper margin of the transducer on the inferior margin of the posterior scapular spine. (Fig. 2)
 - Laterally and distally, follow 90 degrees to the curvature of the humeral head at its more anterolateral insertion on the greater tuberosity. (Fig. 3)
- **Longitudinal Scan:**
 - Proximally, place the transducer in an axial body plane just beneath the posterior acromion process, and



Any patient. Anywhere. Anytime.

This Quick Guide is intended for healthcare professionals and not for patients or consumers. The information in this Quick Guide is provided for general educational purposes, as a convenient quick reference and a supplement to professional experience, education and training, and should not be considered the exclusive source for this type of information. This Quick Guide does not replace or supersede device labeling, including instructions for use, which accompanies any FUJIFILM Sonosite product. At all times, it is the professional responsibility of the practitioner to exercise independent clinical judgment in each particular situation. FUJIFILM Sonosite assumes no responsibility or liability for any misuse of this Quick Guide. SONOSITE and the SONOSITE logo are trademarks and registered trademarks of FUJIFILM Sonosite, Inc. in various jurisdictions. FUJIFILM is a trademark and registered trademark of FUJIFILM Corporation in various jurisdictions. All other trademarks are the property of their respective owners.

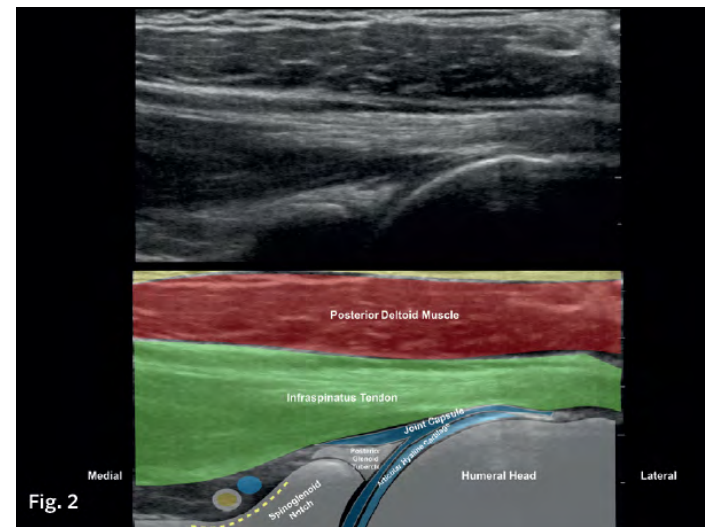
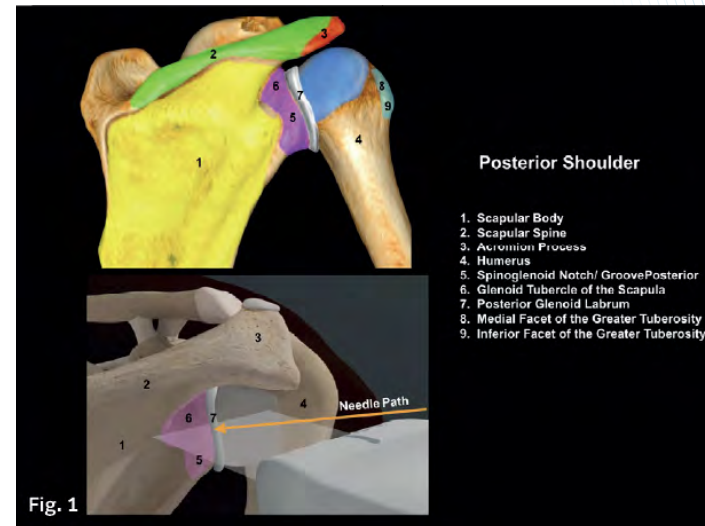
GLENOHUMERAL JOINT INJECTION

Objective:

Image the Glenohumeral (GH) joint for an injection or aspiration for pain relief.

The GH joint is made up from the articulation of the humerus to the glenoid fossa. Since the joint is very mobile, it is stabilized by the four muscles of the rotator cuff: supraspinatus, subscapularis, infraspinatus, and teres minor.

Further stabilization comes from the joint capsule itself, the glenoid labrum, and the GH ligaments. As the shoulder is subject to injury, inflammation, and arthritis, the GH joint can be diagnostically assessed and treated with injections or aspirations utilizing ultrasound-guidance.



Any patient. Anywhere. Anytime.

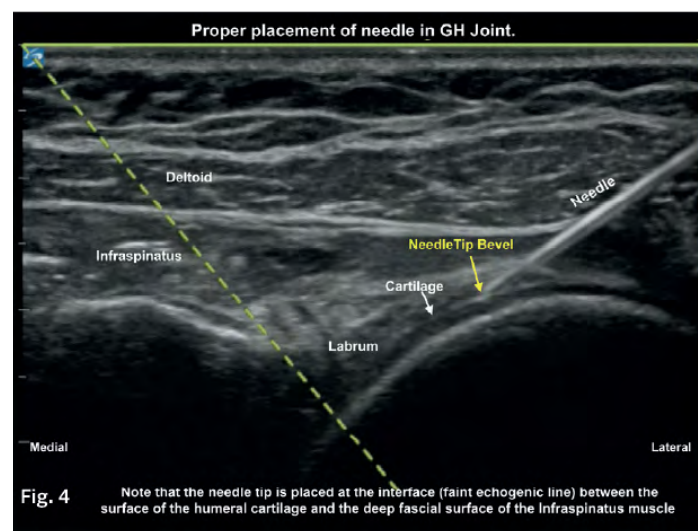
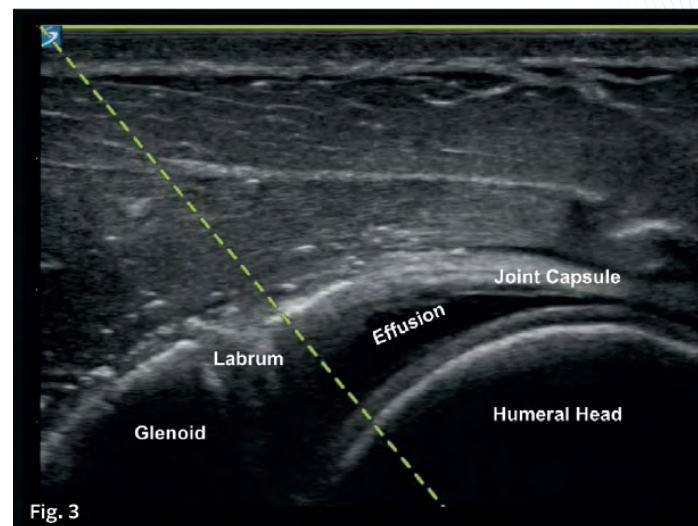
This Quick Guide is intended for healthcare professionals and not for patients or consumers. The information in this Quick Guide is provided for general educational purposes, as a convenient quick reference and a supplement to professional experience, education and training, and should not be considered the exclusive source for this type of information. This Quick Guide does not replace or supersede device labeling, including instructions for use, which accompanies any FUJIFILM Sonosite product. At all times, it is the professional responsibility of the practitioner to exercise independent clinical judgment in each particular situation. FUJIFILM Sonosite assumes no responsibility or liability for any misuse of this Quick Guide. SONOSITE and the SONOSITE logo are trademarks and registered trademarks of FUJIFILM Sonosite, Inc. in various jurisdictions. FUJIFILM is a trademark and registered trademark of FUJIFILM Corporation in various jurisdictions. All other trademarks are the property of their respective owners.

Glenohumeral joint injection

Clinical Pearls:

- Patient Positioning: Place the patient in the contralateral decubitus position, and roll the patient slightly anterior with shoulder to be injected facing skyward.
- Transducer: Use a high frequency linear transducer and the MSK exam type setting at a depth of 3-5 cm.
- Transducer Position: With the operator facing the patient's anterior scapula and lateral humerus, place the transducer in a transverse axis across the back of the shoulder joint. (Fig. 1)
- Unless there is an effusion in the Glenohumeral (GH) joint, the joint space is not often visible. External rotation of the arm can force fluid out of the joint capsule along the humeral head making visualization of the joint space easier. (Fig. 2b)
- Identify the target, which is at the superficial surface of the thin hypoechoic cartilage of the humeral head.
- Measure and save the distance from the skin line to the target area to determine the needed needle length and to document the injection target. (Fig. 3)
- Mark the skin just lateral to the transducer, and then sterilize the site.
- Using a sterile technique, anesthetize down to the capsule, and, if possible, into the shoulder joint.
- With an in-plane needle technique, keep the needle bevel towards the transducer to maximize needle tip visualization. (Fig. 4)
- Do not dig the needle tip into the cartilage or drive the needle tip all the way deep to the labrum.
- If aspiration of fluid is the plan, use a larger needle, and rotate the arm externally to help visualize any joint fluid prior to placing the needle.
- If aspiration is performed first followed by injection, grip and stabilize the needle hub with a hemostat, unscrew the syringe, and replace with the injection syringe.
- Pop the needle through the capsule while staying superficial to the humeral head cartilage.

If the needle tip is in the joint space, there should be little to no resistance during the injection; the fluid will run off into the joint space and **not collect around the needle tip**.



Any patient. Anywhere. Anytime.

This Quick Guide is intended for healthcare professionals and not for patients or consumers. The information in this Quick Guide is provided for general educational purposes, as a convenient quick reference and a supplement to professional experience, education and training, and should not be considered the exclusive source for this type of information. This Quick Guide does not replace or supersede device labeling, including instructions for use, which accompanies any FUJIFILM Sonosite product. At all times, it is the professional responsibility of the practitioner to exercise independent clinical judgment in each particular situation. FUJIFILM Sonosite assumes no responsibility or liability for any misuse of this Quick Guide. SONOSITE and the SONOSITE logo are trademarks and registered trademarks of FUJIFILM Sonosite, Inc. in various jurisdictions. FUJIFILM is a trademark and registered trademark of FUJIFILM Corporation in various jurisdictions. All other trademarks are the property of their respective owners.

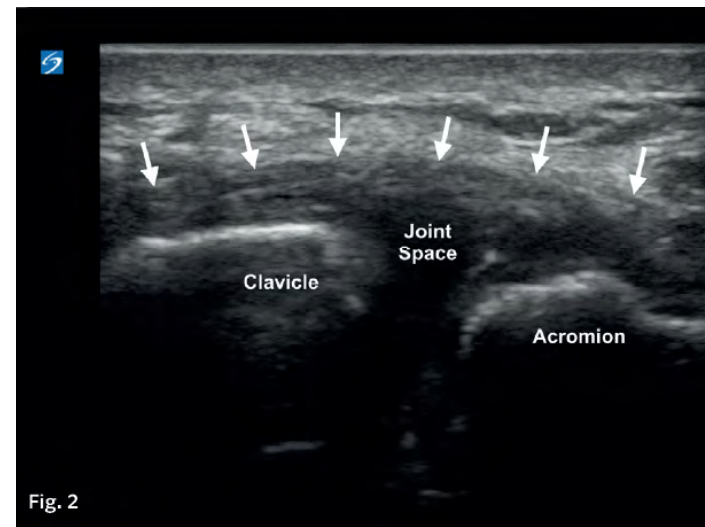
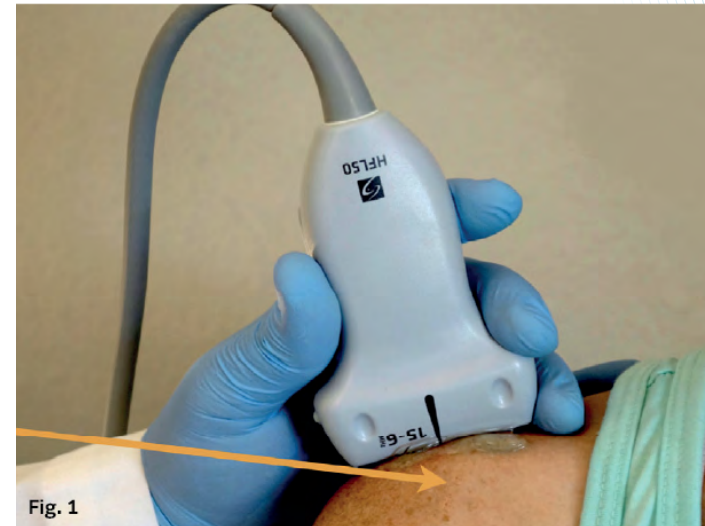AC JOINT INJECTION ACROMIOCLAVICULAR

Objective:

Inject corticosteroids into the intra-articular space of the Acromioclavicular (AC) joint.

AC joint injections are usually taught using a short axis technique, which entails guiding the needle in a perpendicular plane to the beam of the ultrasound.

A far better method is to use the long axis technique, in which the transducer is placed in the frontal/coronal plane as taught with the short axis technique and seen in Fig. 1. The difference is the needle is directed lateral-to-medial into the joint space.



Any patient. Anywhere. Anytime.

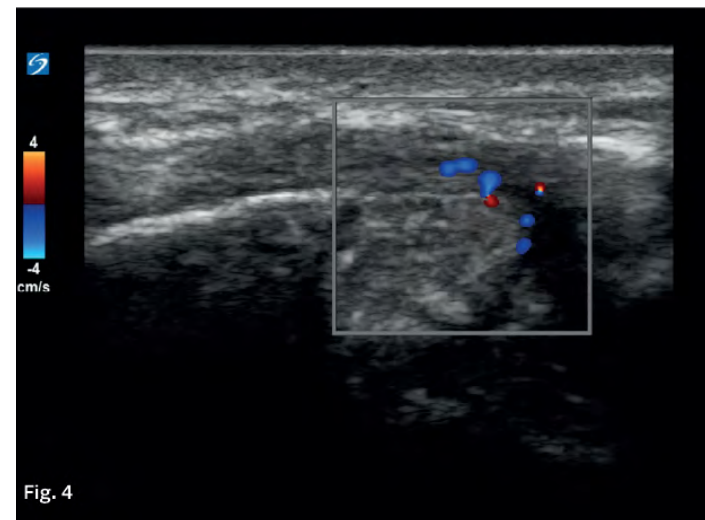
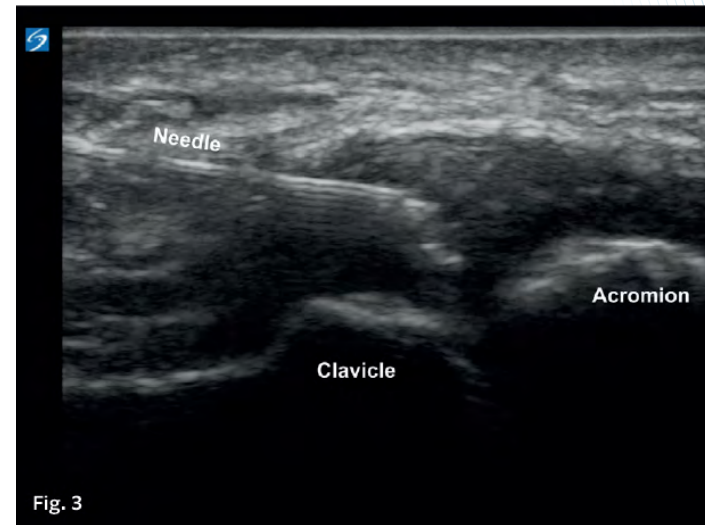
This Quick Guide is intended for healthcare professionals and not for patients or consumers. The information in this Quick Guide is provided for general educational purposes, as a convenient quick reference and a supplement to professional experience, education and training, and should not be considered the exclusive source for this type of information. This Quick Guide does not replace or supersede device labeling, including instructions for use, which accompanies any FUJIFILM Sonosite product. At all times, it is the professional responsibility of the practitioner to exercise independent clinical judgment in each particular situation. FUJIFILM Sonosite assumes no responsibility or liability for any misuse of this Quick Guide. SONOSITE and the SONOSITE logo are trademarks and registered trademarks of FUJIFILM Sonosite, Inc. in various jurisdictions. FUJIFILM is a trademark and registered trademark of FUJIFILM Corporation in various jurisdictions. All other trademarks are the property of their respective owners.

AC joint injection acromioclavicular

Clinical Pearls:

- Patient Positioning: The patient should be seated with the affected arm hanging by their side in a neutral position.
 - The patient's shoulder should be between the ultrasound screen and the operator for direct line of sight.
- Transducer: Use a high frequency linear transducer and the MSK exam type at a depth of 1-2 cm.
- Transducer Position: Place the transducer in the frontal/coronal plane over the AC joint. (Fig. 1)
- Identify the target deep to the AC ligament (Fig. 2, arrows) within the joint capsule.
- Use a sterile technique:
 - Anesthetize the skin lateral to the transducer.
 - Follow the anesthetized track with the operating needle directed in a lateral-to-medial direction into the joint. (Fig. 3)

* Color Doppler may be used to assess for inflammation of the AC joint (Fig. 4), which can occur (e.g. pseudogout).



Any patient. Anywhere. Anytime.

This Quick Guide is intended for healthcare professionals and not for patients or consumers. The information in this Quick Guide is provided for general educational purposes, as a convenient quick reference and a supplement to professional experience, education and training, and should not be considered the exclusive source for this type of information. This Quick Guide does not replace or supersede device labeling, including instructions for use, which accompanies any FUJIFILM Sonosite product. At all times, it is the professional responsibility of the practitioner to exercise independent clinical judgment in each particular situation. FUJIFILM Sonosite assumes no responsibility or liability for any misuse of this Quick Guide. SONOSITE and the SONOSITE logo are trademarks and registered trademarks of FUJIFILM Sonosite, Inc. in various jurisdictions. FUJIFILM is a trademark and registered trademark of FUJIFILM Corporation in various jurisdictions. All other trademarks are the property of their respective owners.

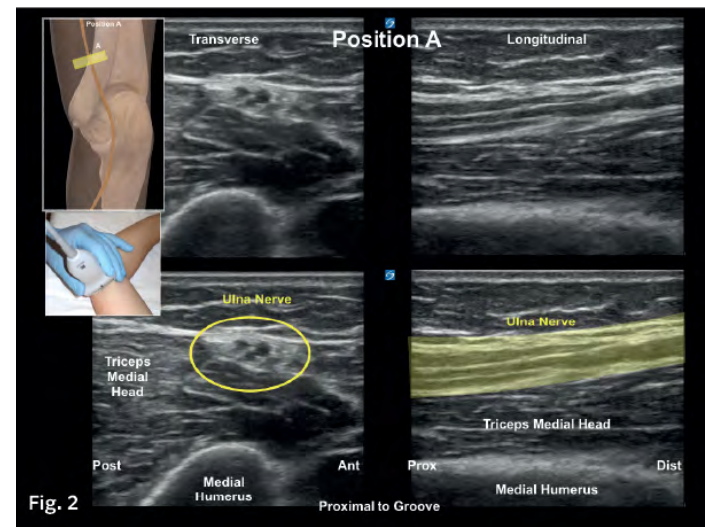
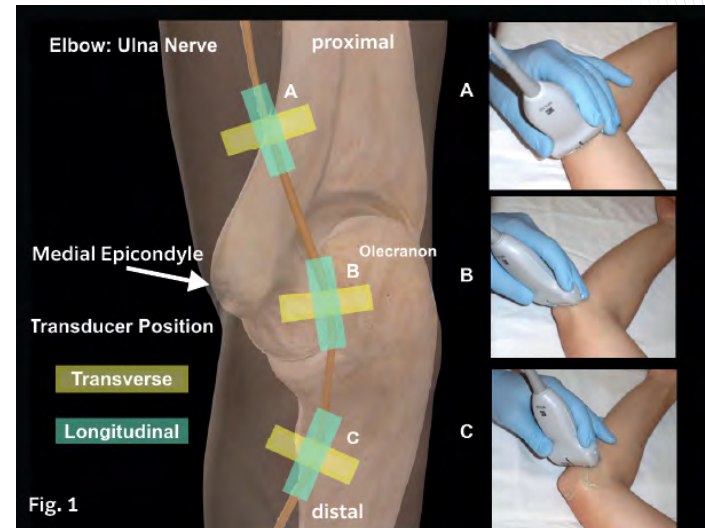
ULNAR NERVE ENTRAPMENT OF THE ELBOW

Objective:

Image the Ulnar Nerve (UN) from just proximal to the medial epicondyle of the humerus to the distal part of the cubital tunnel to look for signs of injury or compression of the UN.

UN entrapment is caused by an injury or compression of the UN, which causes pain, weakness, tingling, or numbness depending on the injury site.

While there are several points of potential compression or injury to the UN, the most common site of entrapment to the UN is at the elbow where it is the least protected and often injured or bumped (e.g. funny bone) as it passes posteriorly to the medial epicondyle of the humerus and groove of the cubital tunnel retinaculum of the elbow.



Any patient. Anywhere. Anytime.

This Quick Guide is intended for healthcare professionals and not for patients or consumers. The information in this Quick Guide is provided for general educational purposes, as a convenient quick reference and a supplement to professional experience, education and training, and should not be considered the exclusive source for this type of information. This Quick Guide does not replace or supersede device labeling, including instructions for use, which accompanies any FUJIFILM Sonosite product. At all times, it is the professional responsibility of the practitioner to exercise independent clinical judgment in each particular situation. FUJIFILM Sonosite assumes no responsibility or liability for any misuse of this Quick Guide. SONOSITE and the SONOSITE logo are trademarks and registered trademarks of FUJIFILM Sonosite, Inc. in various jurisdictions. FUJIFILM is a trademark and registered trademark of FUJIFILM Corporation in various jurisdictions. All other trademarks are the property of their respective owners.

Ulnar nerve entrapment of the elbow

The Ulnar Nerve (UN) originates from the C8 -T1 cervical nerve roots. It travels along the posterior medial edge of the humerus and then posteriorly to the medial epicondyle or groove at the elbow known as the cubital tunnel. It then travels between the two heads of the flexor carpi ulnaris muscles in the forearm to the hand and rests on top of the flexor digitorum profundus.

Clinical Pearls:

- **Patient Positioning:** Place the patient in the supine position with their arm above their head, or place the patient in a seated position with the arm bent behind their back, which gives access to the posterior medial aspect of the distal humerus, elbow, and proximal forearm. (Fig. 1)
- **Transducer:** Use a high frequency linear transducer and the MSK exam type setting at a depth of 1-2 cm.

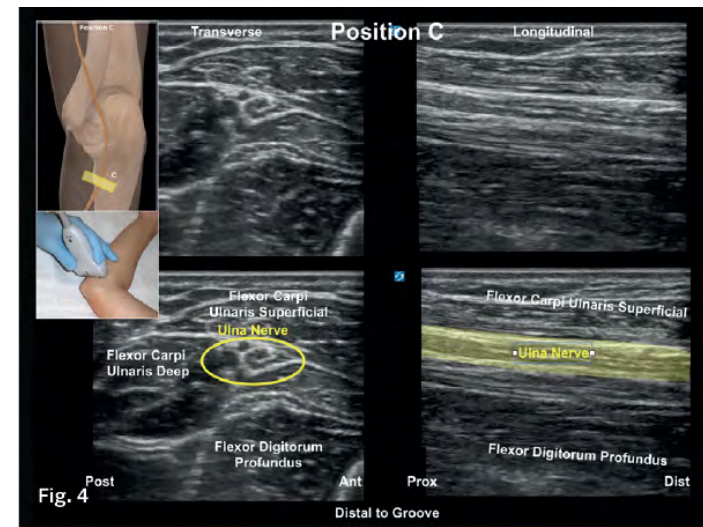
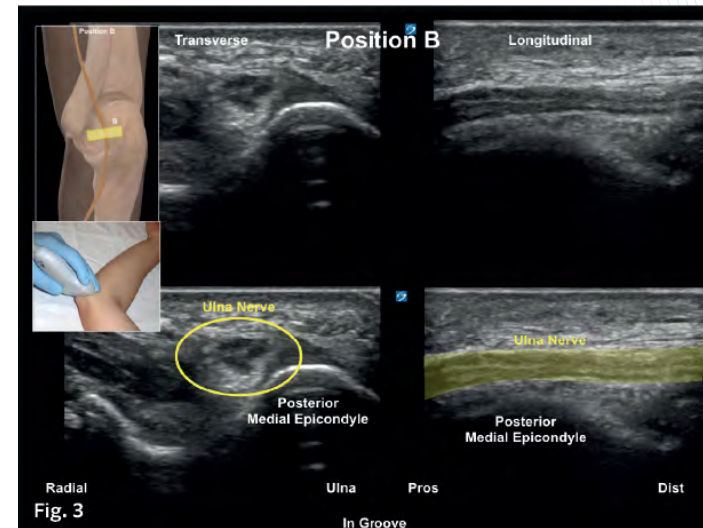
There are three main areas of imaging for UN entrapment of the elbow:

- **Position A:** In the posterior muscular compartment, the UN runs along the humerus near the triceps medial head. (Fig. 2)
 - Place the transducer in the transverse position over the UN proximal to the cubital tunnel, and then rotate to a longitudinal position at the same location.
- **Position B:** The nerve then enters the medial elbow groove, which is known as the cubital tunnel. The roof of the

tunnel is Osborne's ligament, which is also called Osborne's fascia. (Fig. 3)

- Place the transducer in the transverse position over the UN in the cubital tunnel, and then rotate to a longitudinal position at the same location.

- **Position C:** After leaving the cubital tunnel, the UN is found between the two heads of the flexor carpi ulnaris muscles and just posterior to the flexor digitorum profundus muscle. (Fig. 4)
 - Place the transducer in the transverse position over the UN distal to the cubital tunnel between the heads of the flexor carpi ulnaris muscle, and then rotate to a longitudinal position at the same location.



Any patient. Anywhere. Anytime.

This Quick Guide is intended for healthcare professionals and not for patients or consumers. The information in this Quick Guide is provided for general educational purposes, as a convenient quick reference and a supplement to professional experience, education and training, and should not be considered the exclusive source for this type of information. This Quick Guide does not replace or supersede device labeling, including instructions for use, which accompanies any FUJIFILM Sonosite product. At all times, it is the professional responsibility of the practitioner to exercise independent clinical judgment in each particular situation. FUJIFILM Sonosite assumes no responsibility or liability for any misuse of this Quick Guide. SONOSITE and the SONOSITE logo are trademarks and registered trademarks of FUJIFILM Sonosite, Inc. in various jurisdictions. FUJIFILM is a trademark and registered trademark of FUJIFILM Corporation in various jurisdictions. All other trademarks are the property of their respective owners.

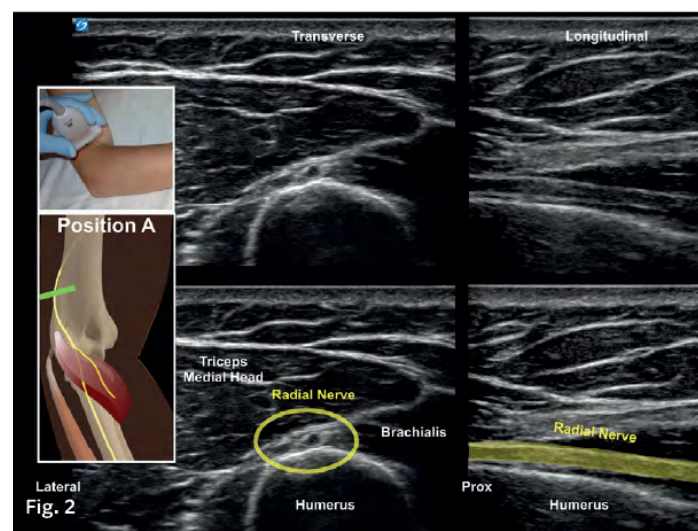
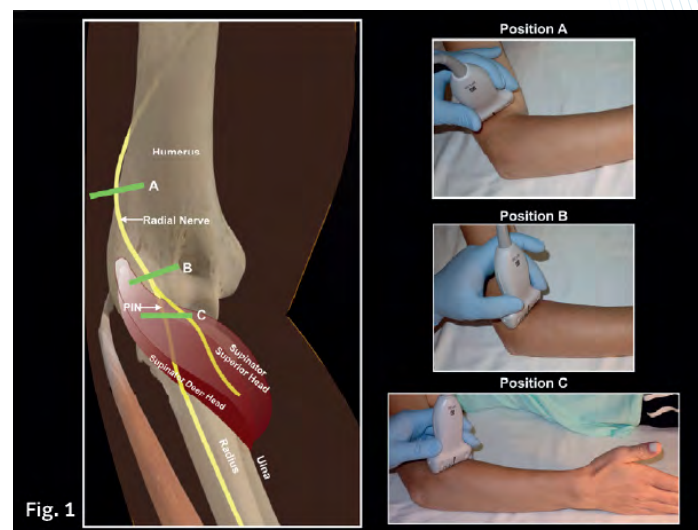
ELBOW: RADIAL NERVE POSTERIOR INTEROSSEOUS BRANCH

Objective:

Image the Radial Nerve (RN) from just distal to the lateral epicondyle of the humerus to where the RN dives deep to the superficial surface of the supinator muscle to look for signs of injury or compression of the RN.

The RN first travels posteriorly as it comes off the brachial plexus and then winds around the lateral aspect of the humerus to a volar position. At the elbow level, it divides into the deeper motor branch known as the Posterior Interosseous Nerve (PIN) and the more superficial sensory branch of the forearm.

There are two main areas for compression and injury of the RN and the PIN. The RN may be damaged by an upper arm penetrating wound or a humeral fracture as the RN tightly wraps around the humerus. It can also become compressed in the septum between the brachialis and the brachioradialis. The PIN can become entrapped by the arcade of Frohse (the supinator arch), which is the most superior portion of the supinator fibrous muscle arch over the PIN.



Any patient. Anywhere. Anytime.

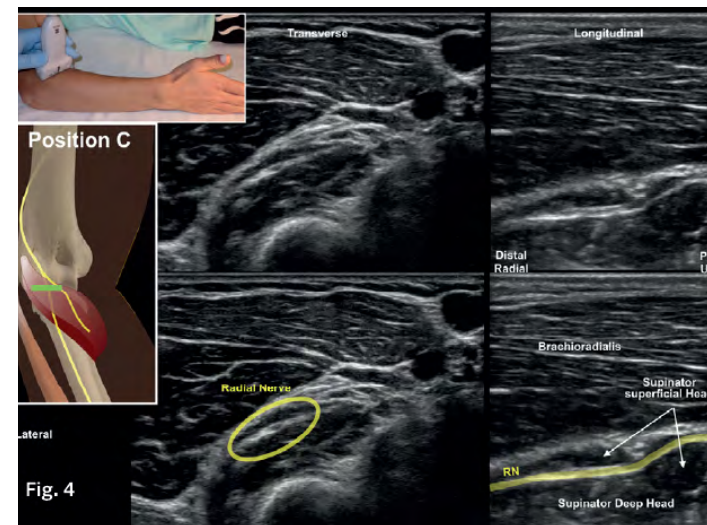
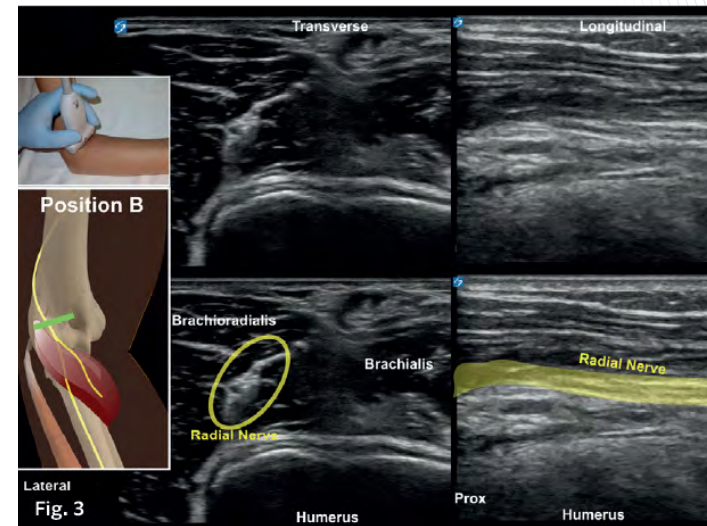
This Quick Guide is intended for healthcare professionals and not for patients or consumers. The information in this Quick Guide is provided for general educational purposes, as a convenient quick reference and a supplement to professional experience, education and training, and should not be considered the exclusive source for this type of information. This Quick Guide does not replace or supersede device labeling, including instructions for use, which accompanies any FUJIFILM Sonosite product. At all times, it is the professional responsibility of the practitioner to exercise independent clinical judgment in each particular situation. FUJIFILM Sonosite assumes no responsibility or liability for any misuse of this Quick Guide. SONOSITE and the SONOSITE logo are trademarks and registered trademarks of FUJIFILM Sonosite, Inc. in various jurisdictions. FUJIFILM is a trademark and registered trademark of FUJIFILM Corporation in various jurisdictions. All other trademarks are the property of their respective owners.

Elbow: Radial nerve

Posterior interosseous branch

Clinical Pearls:

- Patient Positioning: The patient should be in a seated position with the arm resting on a table, the elbow bent, and the thumb pointing towards the ceiling. This allows for access to the lateral aspect of the distal humerus, elbow, and proximal forearm. (Fig. 1)
 - Transducer: Use a high frequency linear transducer and the MSK exam type setting at a depth of 2-3 cm.
- There are three main areas of imaging for the RN at the elbow. For each location, a transverse and longitudinal image should be captured.
- Position A: Image the RN as it travels around from the posterior-to-lateral humerus where it rises out of the humerus' spiral bony groove. (Fig. 2)
 - Place the transducer posteriorly, so that the RN is still in the bony groove. Follow it inferiorly, and watch it lift off the bony groove and enter the brachialis muscle. (Fig. 2)
 - Position B: Image the RN in the septum between the brachioradialis laterally and the brachialis medially. (Fig. 3)
 - Place the transducer in the transverse axis, and continue distally until you see the humeral capitellum covered by hypoechoic cartilage. (Fig. 3)
 - Position C: The PIN is found within the septum between the superficial and deep heads of the supinator muscle at about the level of the radial head. (Fig. 4)
 - Continue distally in the transverse position. The capitellum disappears, and the next distal bony landmark is the radial head. To view the PIN in its longitudinal form, slide the transducer to where the PIN just enters the supinator superficial fascia. This is easier to see if the patient's thumb is pointing skyward. (Fig. 4)



Any patient. Anywhere. Anytime.

This Quick Guide is intended for healthcare professionals and not for patients or consumers. The information in this Quick Guide is provided for general educational purposes, as a convenient quick reference and a supplement to professional experience, education and training, and should not be considered the exclusive source for this type of information. This Quick Guide does not replace or supersede device labeling, including instructions for use, which accompanies any FUJIFILM Sonosite product. At all times, it is the professional responsibility of the practitioner to exercise independent clinical judgment in each particular situation. FUJIFILM Sonosite assumes no responsibility or liability for any misuse of this Quick Guide. SONOSITE and the SONOSITE logo are trademarks and registered trademarks of FUJIFILM Sonosite, Inc. in various jurisdictions. FUJIFILM is a trademark and registered trademark of FUJIFILM Corporation in various jurisdictions. All other trademarks are the property of their respective owners.

ELBOW: MEDIAN NERVE

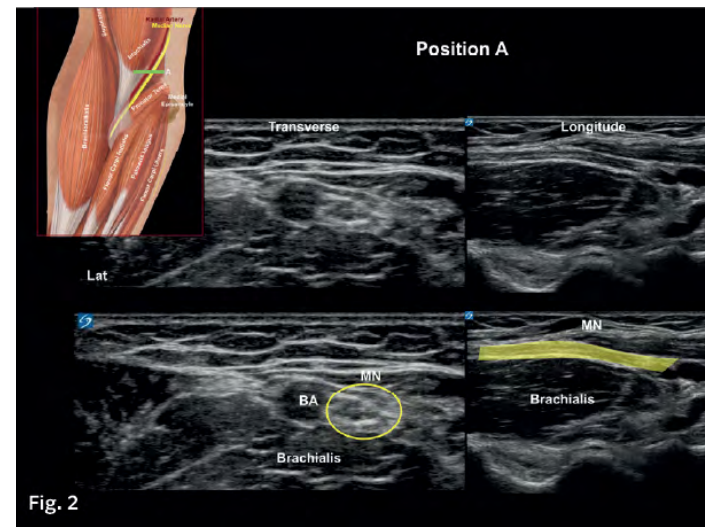
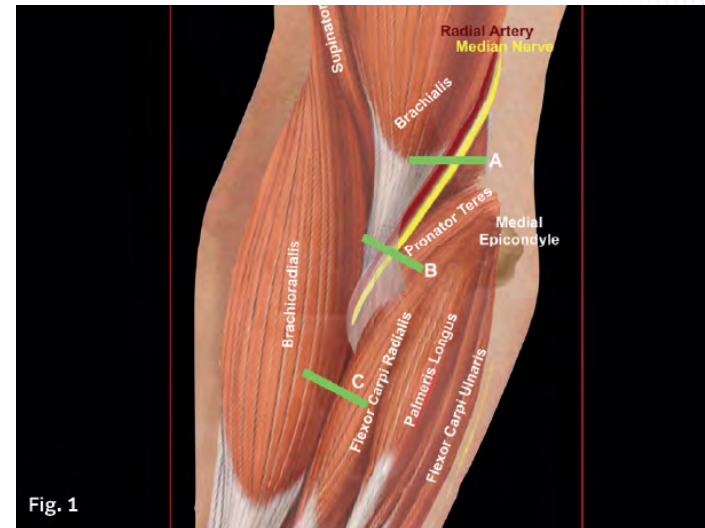
Objective:

Image the Median Nerve (MN) from just proximal to the supracondylar process of the humerus to the superficial surface of the supinator muscle to look for signs of injury or compression of the MN.

The wrist is the most common location for MN entrapment. However, the MN may also become compressed in the elbow by other structures, such as the:

- Proximal humerus and the ligament of struthers
- Proximal elbow near the thickened biceps aponeurosis
- Elbow joint as it passes between the superficial and deep heads of the pronator teres muscles (the most common area of MN compression of the elbow)
- Proximal forearm by the flexor digitorum sublimus muscle

Besides force trauma or injury to the arm, repetitive sport motions such as throwing a ball or weightlifting may also produce irritation or increased muscle mass, which can lead to nerve compression and entrapment.



Any patient. Anywhere. Anytime.

This Quick Guide is intended for healthcare professionals and not for patients or consumers. The information in this Quick Guide is provided for general educational purposes, as a convenient quick reference and a supplement to professional experience, education and training, and should not be considered the exclusive source for this type of information. This Quick Guide does not replace or supersede device labeling, including instructions for use, which accompanies any FUJIFILM Sonosite product. At all times, it is the professional responsibility of the practitioner to exercise independent clinical judgment in each particular situation. FUJIFILM Sonosite assumes no responsibility or liability for any misuse of this Quick Guide. SONOSITE and the SONOSITE logo are trademarks and registered trademarks of FUJIFILM Sonosite, Inc. in various jurisdictions. FUJIFILM is a trademark and registered trademark of FUJIFILM Corporation in various jurisdictions. All other trademarks are the property of their respective owners.

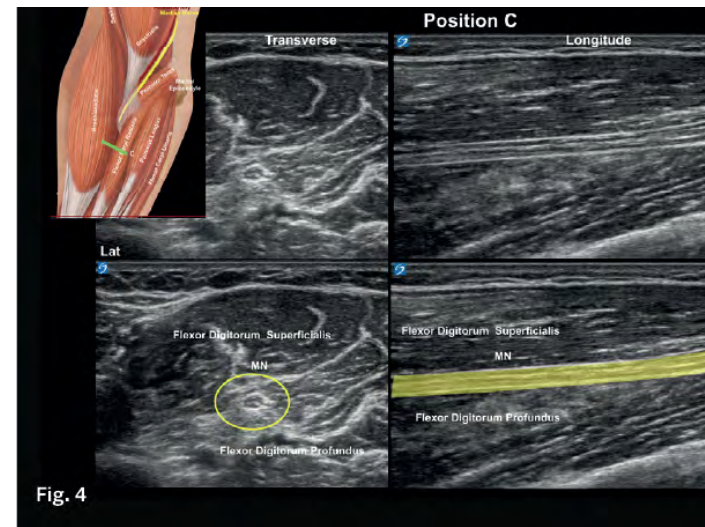
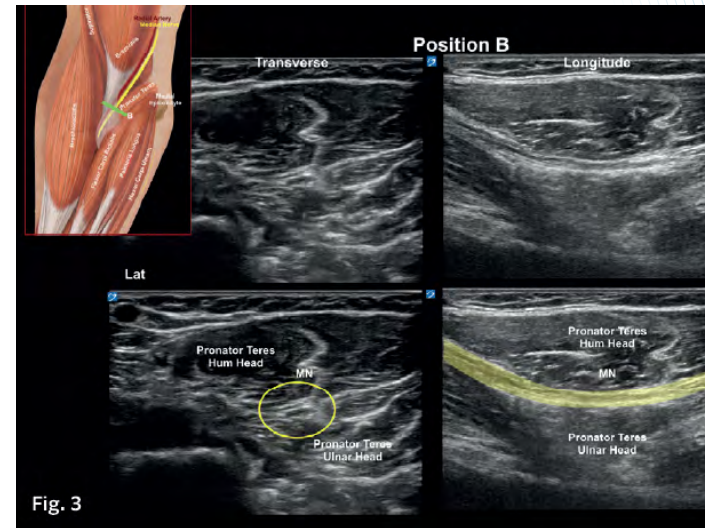
Elbow: Median nerve

The Median Nerve (MN) arises from the cervical nerve roots of C6-T1. As part of the medial and lateral cords off the brachial plexus, the MN travels alongside the brachial artery on the anterior aspect of the arm and elbow and passes through the antecubital fossa between the biceps aponeurosis and the brachialis muscle. The MN then passes between the superficial and deep heads of the pronator teres muscle at the level of the elbow joint where it enters the anterior compartment of the forearm by passing beneath the fibrous arch of the heads of the Flexor Digitorum Superficialis (FDS) and the Flexor Digitorum Profundus (FDP) muscles.

Clinical Pearls:

- Patient Positioning: Place the patient in a seated position with the arm extended comfortably and resting on the table with the palm supinated.
- Transducer: Use a high frequency linear transducer and the MSK exam type setting at a depth of 2-3 cm.
- Position A: Locate the brachial artery, and position the transducer over the humeral capitellum/trochlea area of the distal humerus. The MN lies immediately medial to the brachial artery. (Fig. 2)
- Position B: Slide the transducer slowly distally until you are about 3 cm distal to the elbow joint space where the MN lies between the heads of the pronator teres. (Fig. 3)
- Position C: Slide the transducer distally until the MN is seen between the FDS and the FDP muscle bellies. - It is helpful to have the patient flex and extend the second and third fingers to help identify the FDS and FDP tendons. (Fig. 4)
- This is a common point of proximal MN entrapment.

There are three main areas for imaging the MN at the elbow. For each location, a transverse and longitudinal image should be captured.



Any patient. Anywhere. Anytime.

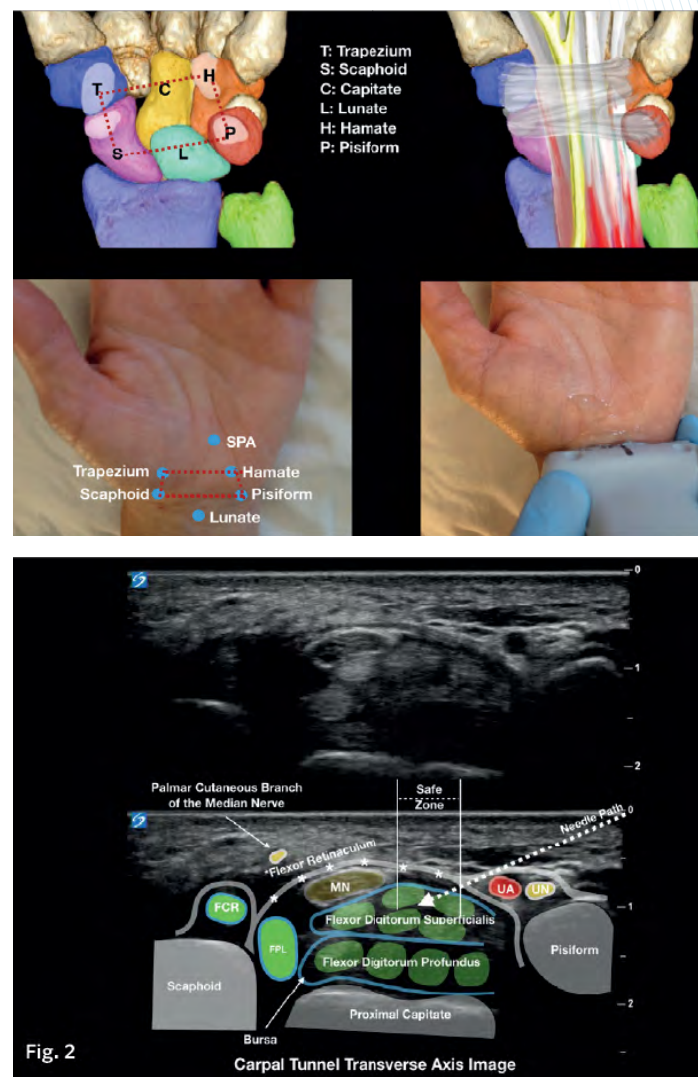
This Quick Guide is intended for healthcare professionals and not for patients or consumers. The information in this Quick Guide is provided for general educational purposes, as a convenient quick reference and a supplement to professional experience, education and training, and should not be considered the exclusive source for this type of information. This Quick Guide does not replace or supersede device labeling, including instructions for use, which accompanies any FUJIFILM Sonosite product. At all times, it is the professional responsibility of the practitioner to exercise independent clinical judgment in each particular situation. FUJIFILM Sonosite assumes no responsibility or liability for any misuse of this Quick Guide. SONOSITE and the SONOSITE logo are trademarks and registered trademarks of FUJIFILM Sonosite, Inc. in various jurisdictions. FUJIFILM is a trademark and registered trademark of FUJIFILM Corporation in various jurisdictions. All other trademarks are the property of their respective owners.

CARPAL TUNNEL INJECTION

Objective:

Place corticosteroids into the proximal Carpal Tunnel (CT) within the tendon sheaths or the bursae folds that are located between the flexor digitorum superficialis and/or the flexor digitorum profundus.

CT injections are commonly performed to alleviate inflammation of the tendons and bursae within the CT that can swell and compress against the Median Nerve (MN), which causes numbness and loss of normal function.



Any patient. Anywhere. Anytime.

This Quick Guide is intended for healthcare professionals and not for patients or consumers. The information in this Quick Guide is provided for general educational purposes, as a convenient quick reference and a supplement to professional experience, education and training, and should not be considered the exclusive source for this type of information. This Quick Guide does not replace or supersede device labeling, including instructions for use, which accompanies any FUJIFILM Sonosite product. At all times, it is the professional responsibility of the practitioner to exercise independent clinical judgment in each particular situation. FUJIFILM Sonosite assumes no responsibility or liability for any misuse of this Quick Guide. SONOSITE and the SONOSITE logo are trademarks and registered trademarks of FUJIFILM Sonosite, Inc. in various jurisdictions. FUJIFILM is a trademark and registered trademark of FUJIFILM Corporation in various jurisdictions. All other trademarks are the property of their respective owners.

Carpal tunnel injection

Clinical Pearls:

- Patient Positioning: Have the patient lie down with the arm out to the side on a tray or table and the wrist in hyperextension with the palm facing up.
- The patient should be between the ultrasound machine and examiner for optimum line of sight during the procedure.
- Transducer: Use a high frequency linear transducer and the MSK exam type setting at a depth of 2-3 cm.
- Use color Doppler to see important vessels.

Anatomy:

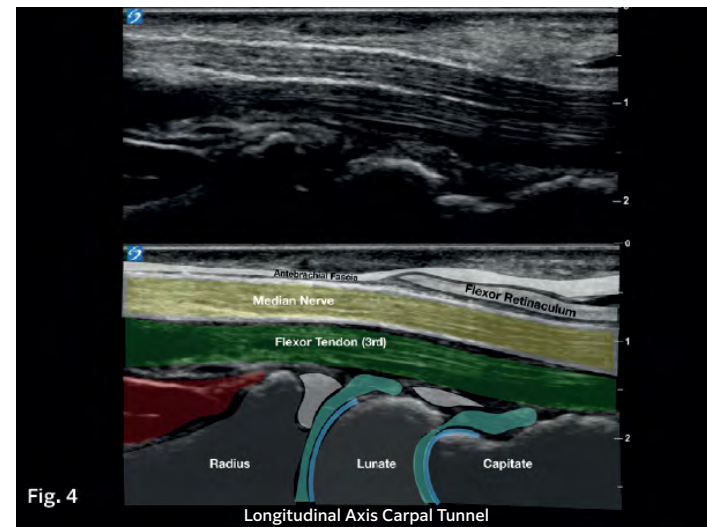
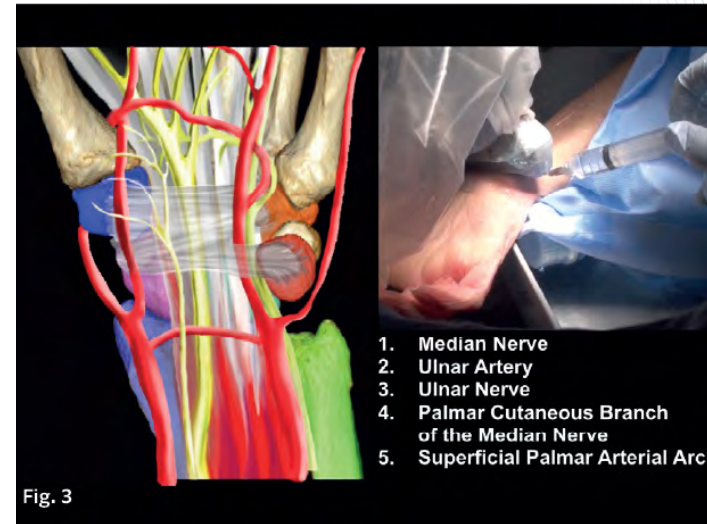
- The Carpal Tunnel (CT) is a square-shaped box defined by lines connecting the Scaphoid (S) tubercle to the Trapezium (T), the T to the Hamate (H) hook, the H hook to the Pisiform (P), and the P to the S tubercle. (Fig. 1)
- Locate and mark the Superficial Palmar Arterial (SPA) arch using the color feature. (Fig. 1)
- The “anatomical safe zone” should be identified as the space between Guyon’s canal and the Median Nerve

(MN). The ulnar nerve is between the ulnar artery and the pisiform bone within Guyon’s canal and creates the ulnar border of the “anatomical safe zone.” (Fig. 2)

- Check for anatomic variants such as bifid MN and persistent median artery before placing the needle.
- Injecting ulnar to the MN will avoid potentially damaging the palmar cutaneous branch of the MN. (Fig. 3)

Procedure Tips:

- Moving the transducer radially will help shorten the needle throw to the “anatomical safe zone” when advancing over the Guyon’s canal location.
- Placing a large amount of sterile gel over the pisiform can help achieve the trajectory necessary for advancing the needle over Guyon’s canal and into the “anatomical safe zone.”
- When injecting, it can be helpful to rotate the transducer to the long axis, and confirm that the injectate has spread throughout the CT and not into the MN. (Fig. 4)



Any patient. Anywhere. Anytime.

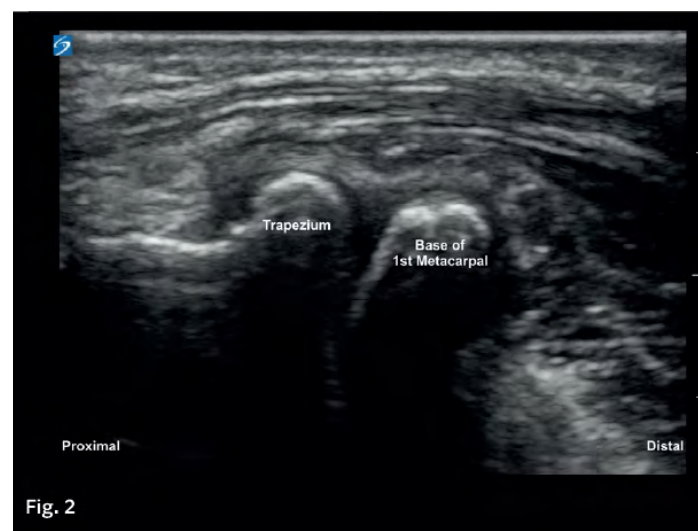
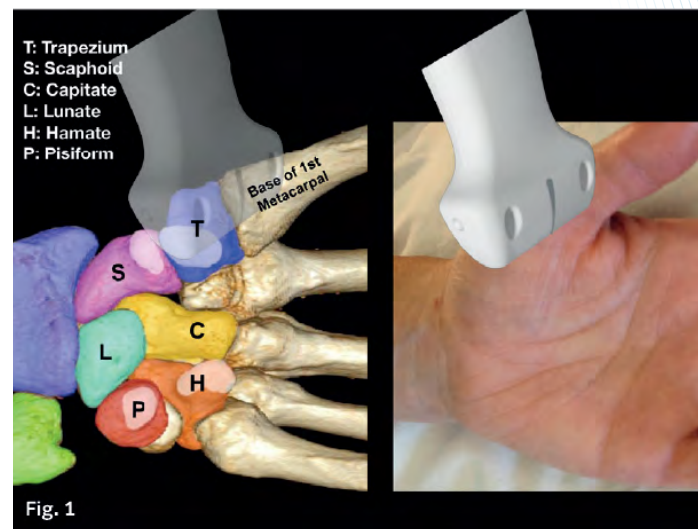
This Quick Guide is intended for healthcare professionals and not for patients or consumers. The information in this Quick Guide is provided for general educational purposes, as a convenient quick reference and a supplement to professional experience, education and training, and should not be considered the exclusive source for this type of information. This Quick Guide does not replace or supersede device labeling, including instructions for use, which accompanies any FUJIFILM Sonosite product. At all times, it is the professional responsibility of the practitioner to exercise independent clinical judgment in each particular situation. FUJIFILM Sonosite assumes no responsibility or liability for any misuse of this Quick Guide. SONOSITE and the SONOSITE logo are trademarks and registered trademarks of FUJIFILM Sonosite, Inc. in various jurisdictions. FUJIFILM is a trademark and registered trademark of FUJIFILM Corporation in various jurisdictions. All other trademarks are the property of their respective owners.

CARPOMETACARPAL JOINT INJECTION

Objective:

Image the Carpometacarpal (CMC) joint for the detection of osteoarthritis and possible injection of steroids.

The CMC joint is between the base of the first metacarpal long bone of the thumb and the trapezium carpal bone of the wrist. The CMC joint is crucial for the human hand to function, and it is also one of the most commonly affected joints for painful osteoarthritis. Corticosteroid injections into the joint are often performed for symptom relief and temporary return of hand capability.



Any patient. Anywhere. Anytime.

This Quick Guide is intended for healthcare professionals and not for patients or consumers. The information in this Quick Guide is provided for general educational purposes, as a convenient quick reference and a supplement to professional experience, education and training, and should not be considered the exclusive source for this type of information. This Quick Guide does not replace or supersede device labeling, including instructions for use, which accompanies any FUJIFILM Sonosite product. At all times, it is the professional responsibility of the practitioner to exercise independent clinical judgment in each particular situation. FUJIFILM Sonosite assumes no responsibility or liability for any misuse of this Quick Guide. SONOSITE and the SONOSITE logo are trademarks and registered trademarks of FUJIFILM Sonosite, Inc. in various jurisdictions. FUJIFILM is a trademark and registered trademark of FUJIFILM Corporation in various jurisdictions. All other trademarks are the property of their respective owners.

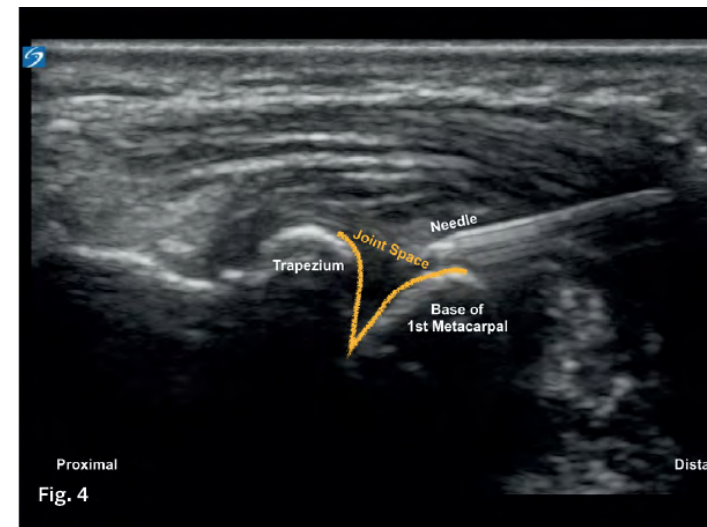
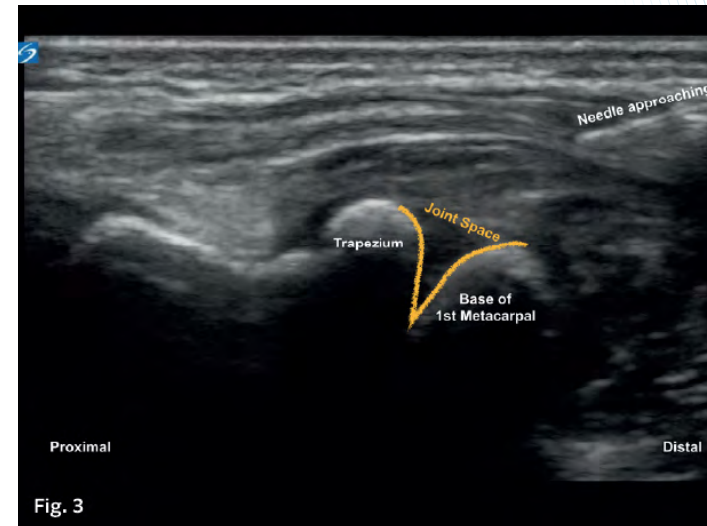
Carpometacarpal joint injection

The dorsal approach endangers the radial artery, which dives dorsally just distal to the lateral radial styloid. A palmar approach is a better technique for injecting the joint, since it avoids potential damage to the artery.

Osteophytes are usually present, which can further block access to the joint. Using the palmar approach, the operator can choose either a proximal-to-distal or a distal-to-proximal needle path.

Clinical Pearls:

- Patient Positioning: The patient should be seated with the hand resting on a table in a supinated position.
- Transducer: Use a smaller high frequency linear transducer and the MSK exam type setting at a depth of 2 cm.
- Transducer Position: Place the transducer along the palmar aspect or the thumb Carpometacarpal (CMC) joint. (Fig. 1)
- To ensure you are seeing the CMC joint and not trapezioscapoid joint, with the transducer in place, grasp the patient's thumb metacarpal bone proximal to the Metacarpophalangeal (MCP) joint, and move it back and forth to get the CMC joint to move.
- Decide whether you will use the distal-to-proximal or the proximal-to-distal needle path. (Fig. 2)
- Color Doppler may be used to ensure there are no vessels within your chosen needle path.
- Using a sterile technique and ultrasound-guidance; anesthetize the skin lateral to the transducer.
- Follow the anesthetized track, and guide the operating needle and medication-containing syringe using ultrasound.
- Since the CMC joint space is a relatively small joint space, use no more than 1 cc total of injectate, and inject slowly to avoid pain when stretching the joint membrane.



Any patient. Anywhere. Anytime.

This Quick Guide is intended for healthcare professionals and not for patients or consumers. The information in this Quick Guide is provided for general educational purposes, as a convenient quick reference and a supplement to professional experience, education and training, and should not be considered the exclusive source for this type of information. This Quick Guide does not replace or supersede device labeling, including instructions for use, which accompanies any FUJIFILM Sonosite product. At all times, it is the professional responsibility of the practitioner to exercise independent clinical judgment in each particular situation. FUJIFILM Sonosite assumes no responsibility or liability for any misuse of this Quick Guide. SONOSITE and the SONOSITE logo are trademarks and registered trademarks of FUJIFILM Sonosite, Inc. in various jurisdictions. FUJIFILM is a trademark and registered trademark of FUJIFILM Corporation in various jurisdictions. All other trademarks are the property of their respective owners.

TRIGGER FINGER INJECTION

Objective:

Image the problematic trigger finger with ultrasound-guidance for a corticosteroid injection.

Trigger finger occurs when inflammation and swelling of the sheath or pulley surround an affected tendon, which restricts motion. Also known as stenosing tenosynovitis, trigger finger may cause the finger to snap while bending or straightening the finger, which causes severe pain or causes the finger to lock in place. People who perform repetitive finger movements, do repeated gripping actions, or have diabetes are at a higher risk of developing trigger finger. A proper injection of the trigger finger may relieve the triggering in almost all cases.



Fig. 1

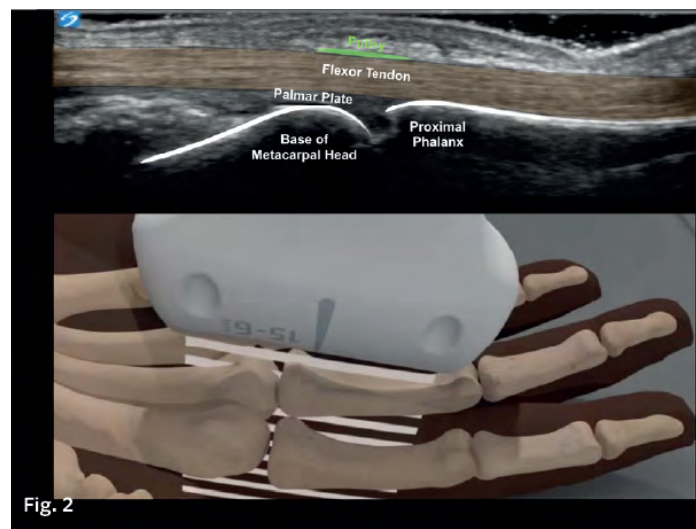


Fig. 2

Any patient. Anywhere. Anytime.

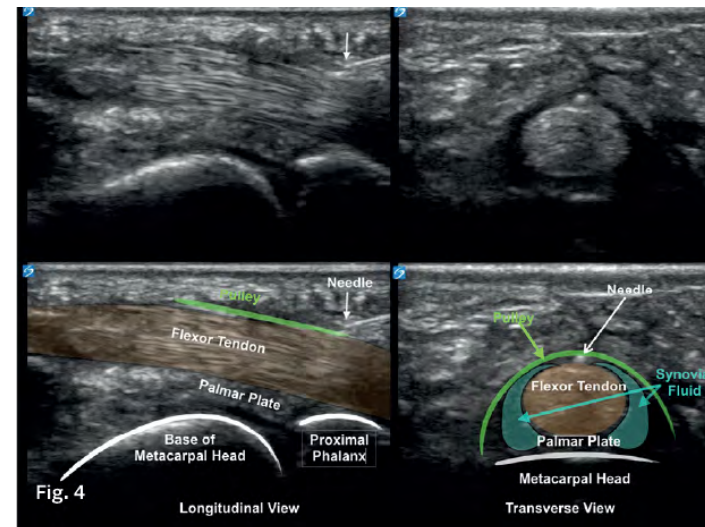
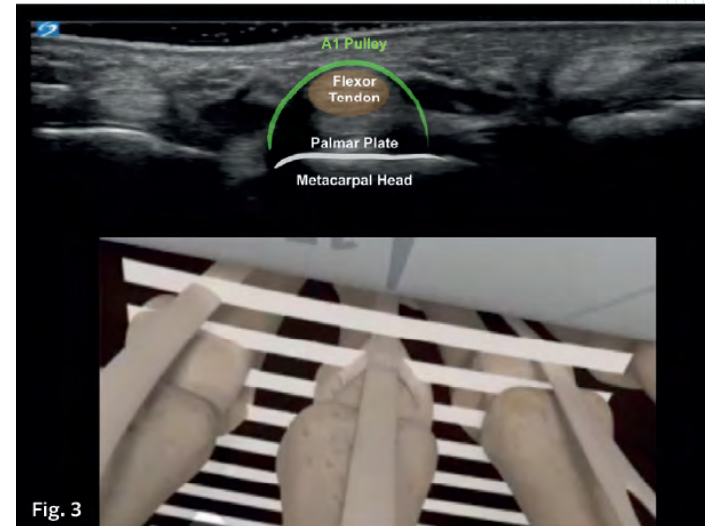
This Quick Guide is intended for healthcare professionals and not for patients or consumers. The information in this Quick Guide is provided for general educational purposes, as a convenient quick reference and a supplement to professional experience, education and training, and should not be considered the exclusive source for this type of information. This Quick Guide does not replace or supersede device labeling, including instructions for use, which accompanies any FUJIFILM Sonosite product. At all times, it is the professional responsibility of the practitioner to exercise independent clinical judgment in each particular situation. FUJIFILM Sonosite assumes no responsibility or liability for any misuse of this Quick Guide. SONOSITE and the SONOSITE logo are trademarks and registered trademarks of FUJIFILM Sonosite, Inc. in various jurisdictions. FUJIFILM is a trademark and registered trademark of FUJIFILM Corporation in various jurisdictions. All other trademarks are the property of their respective owners.

Trigger finger injection

In trigger finger, the flexor tendon bundle's motion, which is normally a smooth gliding motion over the Metacarpophalangeal (MCP) joint, is hampered by a swollen and tightened A1 pulley. The pulley is a thickening of the synovial tendon sheath that completely encircles the tendon. It connects to the palmar plate, and it extends distally from the junction of the metacarpal shaft and head to the junction of the proximal phalanx base and shaft. The pulley's function is to prevent the tendon from bowstringing away from the bone and maintain its smooth gliding motion on the palmar plate. The plate is a triangular piece of fibrocartilage that has its base along the base of the proximal phalanx and its tip pointing proximally. It slides along the cartilage of the metacarpal head's palmar surface.

Clinical Pearls:

- Patient Positioning: For digits 2-5, place the affected hand in supination on a table. For trigger thumbs, position the patient in the supine position with the affected hand raised over their head. This exposes the thumb flexor tendon optimally and makes the injection much easier.
- Transducer: Use a high frequency linear transducer and the MSK exam type setting at a depth of 1-2 cm.
- Transducer Position: Place the transducer in the anatomic sagittal plane over the palmar aspect of the MCP joint of the affected digit. (Fig. 1)
- Decide whether you will use the distal-to-proximal or the proximal-to-distal direction for your injection path. (Fig. 2)
- Color Doppler may be used to ensure there are no neurovascular bundles
- along your chosen needle path.
- Use a sterile technique and ultrasound-guidance; anesthetize the skin lateral to the transducer.
- Under ultrasound-guidance, the injection is performed by aiming the needle tip at the space between the tendon palmar surface and the deep surface of the tendon sheath. (Fig. 3)
- Verify your needle position by rotating your transducer 90 degrees in the transverse view. (Fig. 4)
- A correctly placed needle tip will result in the injectate flowing along the tendon surface in the space deep to the tendon sheath with very little resistance, and it is seen quite easily on ultrasound.



Any patient. Anywhere. Anytime.

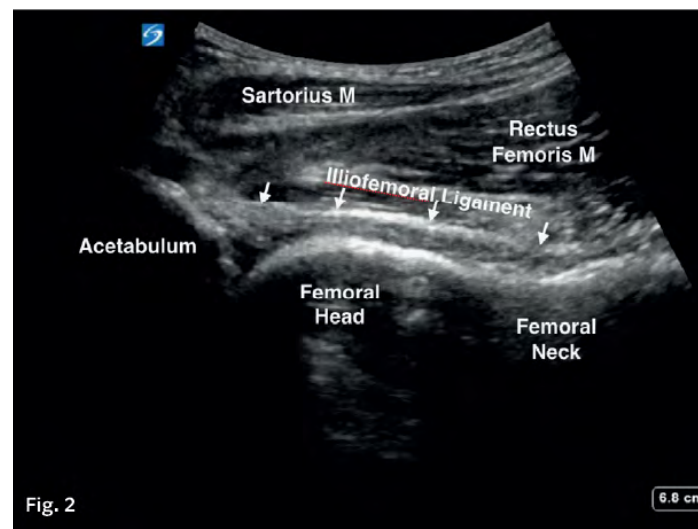
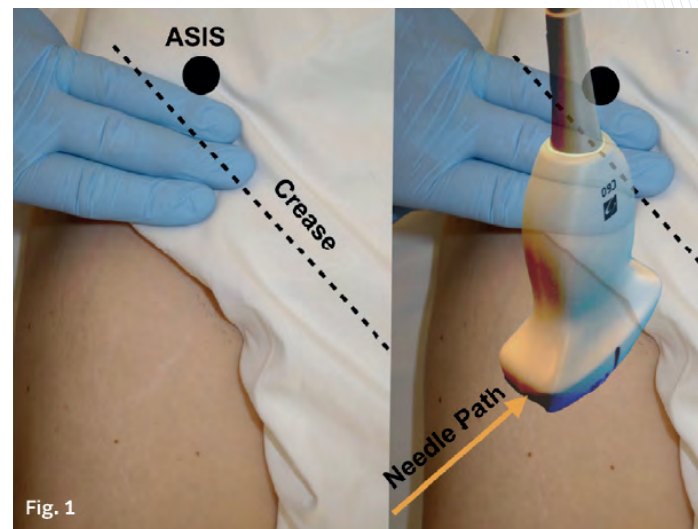
This Quick Guide is intended for healthcare professionals and not for patients or consumers. The information in this Quick Guide is provided for general educational purposes, as a convenient quick reference and a supplement to professional experience, education and training, and should not be considered the exclusive source for this type of information. This Quick Guide does not replace or supersede device labeling, including instructions for use, which accompanies any FUJIFILM Sonosite product. At all times, it is the professional responsibility of the practitioner to exercise independent clinical judgment in each particular situation. FUJIFILM Sonosite assumes no responsibility or liability for any misuse of this Quick Guide. SONOSITE and the SONOSITE logo are trademarks and registered trademarks of FUJIFILM Sonosite, Inc. in various jurisdictions. FUJIFILM is a trademark and registered trademark of FUJIFILM Corporation in various jurisdictions. All other trademarks are the property of their respective owners.

HIP JOINT INJECTION

Objective:

Use ultrasound-guidance to examine the intra-articular joint space for aspirations and injections.

Injection of the hip joint is a commonly performed procedure. When done blind, the injection usually misses the joint. Since the hip is one of the largest joints in the body, guiding a hip joint injection with ultrasound is relatively easy to do.



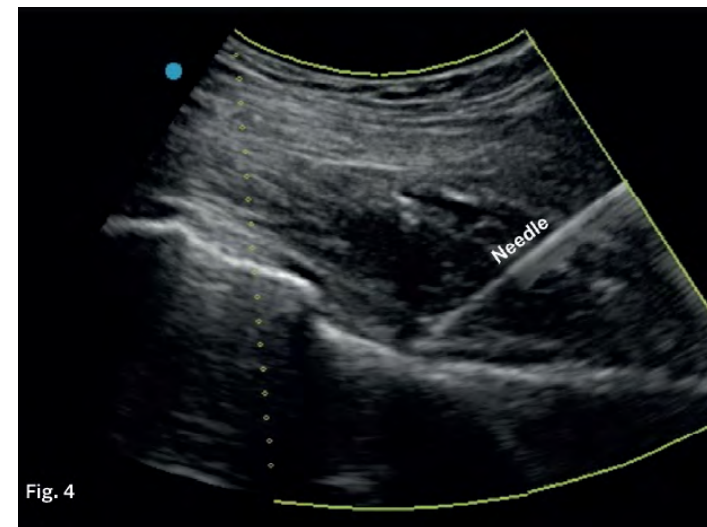
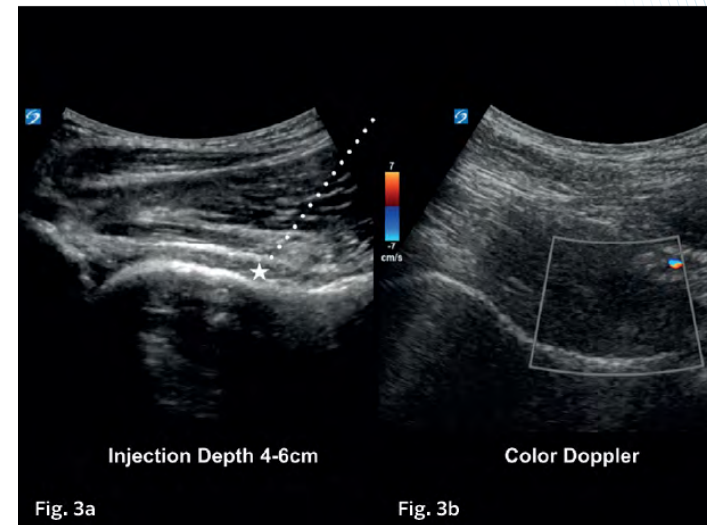
Any patient. Anywhere. Anytime.

This Quick Guide is intended for healthcare professionals and not for patients or consumers. The information in this Quick Guide is provided for general educational purposes, as a convenient quick reference and a supplement to professional experience, education and training, and should not be considered the exclusive source for this type of information. This Quick Guide does not replace or supersede device labeling, including instructions for use, which accompanies any FUJIFILM Sonosite product. At all times, it is the professional responsibility of the practitioner to exercise independent clinical judgment in each particular situation. FUJIFILM Sonosite assumes no responsibility or liability for any misuse of this Quick Guide. SONOSITE and the SONOSITE logo are trademarks and registered trademarks of FUJIFILM Sonosite, Inc. in various jurisdictions. FUJIFILM is a trademark and registered trademark of FUJIFILM Corporation in various jurisdictions. All other trademarks are the property of their respective owners.

Hip joint injection

Clinical Pearls:

- Remove undergarments that impede access to the hip crease.
- Patient Positioning: Place the patient in a supine position with the leg extended and the toes pointing inward.
- Transducer: Use a curved array transducer and the MSK exam type at a depth of 4-9 cm.
- Transducer Position: Place the transducer 4 cm distal to the Anterior Superior Iliac Spine (ASIS) directed to the umbilicus. (Fig. 1)
- The anatomy is identified in Fig. 2.
- Identify the target and measure the needle path. (Fig. 3a)
- Use color Doppler to identify the surrounding vessels and anatomy. (Fig. 3b)
- Sterilize the skin, and anesthetize lateral to the transducer.
- Note the angle of the needle to the skin for planning proper needle trajectory.
- With the BEVEL UP, advance the needle to the inside joint space target. (Fig. 4)
- Verify the needle position in the transverse plane.
- There should be little to no resistance to the flow of the injectate during the injection.



Any patient. Anywhere. Anytime.

This Quick Guide is intended for healthcare professionals and not for patients or consumers. The information in this Quick Guide is provided for general educational purposes, as a convenient quick reference and a supplement to professional experience, education and training, and should not be considered the exclusive source for this type of information. This Quick Guide does not replace or supersede device labeling, including instructions for use, which accompanies any FUJIFILM Sonosite product. At all times, it is the professional responsibility of the practitioner to exercise independent clinical judgment in each particular situation. FUJIFILM Sonosite assumes no responsibility or liability for any misuse of this Quick Guide. SONOSITE and the SONOSITE logo are trademarks and registered trademarks of FUJIFILM Sonosite, Inc. in various jurisdictions. FUJIFILM is a trademark and registered trademark of FUJIFILM Corporation in various jurisdictions. All other trademarks are the property of their respective owners.

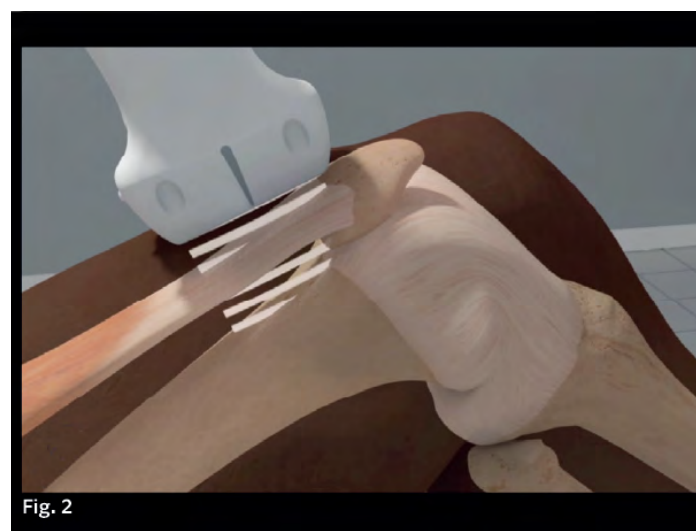
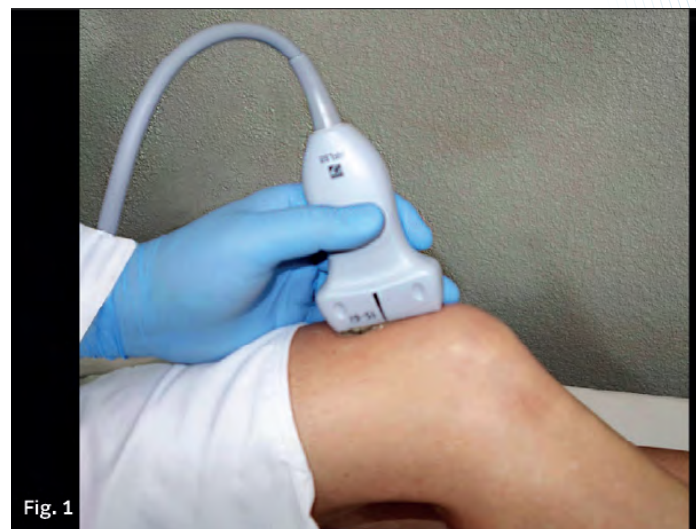SUPRAPATELLAR RECESS

Longitudinal scanning the lateral suprapatellar recess of the knee

Objective:

Assess the suprapatellar recess in the longitudinal view to confirm intra-articular needle tip position, and assess the quadriceps tendon for enthesopathies at the patella.

The knee joint has several compartments. All of them are contiguous in most people, so a substance injected into any one of them will distribute into the entire joint. The joint space is at the interface of the prefemoral fat pad and the deep surface of the quadriceps tendon fascia. It is usually easily visible when there is fluid in the joint space, which makes the lateral suprapatellar recess, often called the suprapatellar “bursa,” the easiest compartment to access. Before placing a needle into the suprapatellar recess, it is best to start with a longitudinal view to determine how much fluid is in the joint or if the knee will be a “dry” target that will require further maneuvering to identify the recess borders.



Any patient. Anywhere. Anytime.

This Quick Guide is intended for healthcare professionals and not for patients or consumers. The information in this Quick Guide is provided for general educational purposes, as a convenient quick reference and a supplement to professional experience, education and training, and should not be considered the exclusive source for this type of information. This Quick Guide does not replace or supersede device labeling, including instructions for use, which accompanies any FUJIFILM Sonosite product. At all times, it is the professional responsibility of the practitioner to exercise independent clinical judgment in each particular situation. FUJIFILM Sonosite assumes no responsibility or liability for any misuse of this Quick Guide. SONOSITE and the SONOSITE logo are trademarks and registered trademarks of FUJIFILM Sonosite, Inc. in various jurisdictions. FUJIFILM is a trademark and registered trademark of FUJIFILM Corporation in various jurisdictions. All other trademarks are the property of their respective owners.

Suprapatellar recess

Longitudinal scanning the lateral suprapatellar recess of the knee

While scanning, you can help identify the suprapatellar recess by using a finger to push on the skin on the medial and lateral sides of the joint. This will move the fat pad. The quadriceps tendon is anchored by four large muscles and will not move during manipulation.

Clinical Pearls:

- Patient Positioning: Place the patient in a supine or seated position with the knee slightly bent 30 degrees and the toes pointed toward the ceiling. (Fig. 1)
- Transducer: Use a high frequency linear transducer and the MSK exam type setting at a depth of 3 cm.
- Transducer Position: Place the transducer in the longitudinal plane midline over the distal thigh and proximal to the knee to obtain the longitudinal image of the suprapatellar recess. (Fig. 2)
- Note there are two separate fat pads: The large prefemoral fat pad and the small triangular quadriceps fat pad, which is not connected to the prefemoral fat pad. Instead, it is connected to the quadriceps tendon deep fascia and patella. (Fig. 3 and Fig. 4)
- Scan through the quadriceps tendon, and extend over to the medial and lateral sides, as small amounts of synovial fluid will tend to accumulate in the more dependent areas of the suprapatellar recess.
- Increasing pressure of the transducer or squeezing the knee during dynamic scanning may help to detect small effusions or differentiate effusions from synovial thickening.
- Fluid in the knee joint will appear as an anechoic or hypoechoic area. (Fig. 3 and Fig. 4)

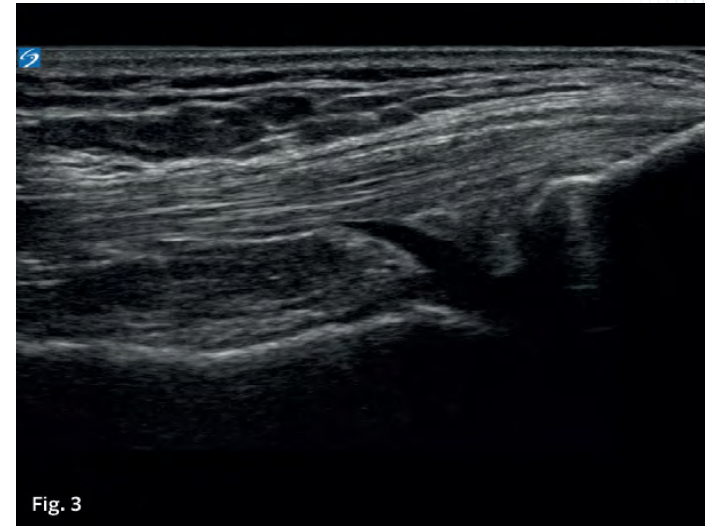


Fig. 3

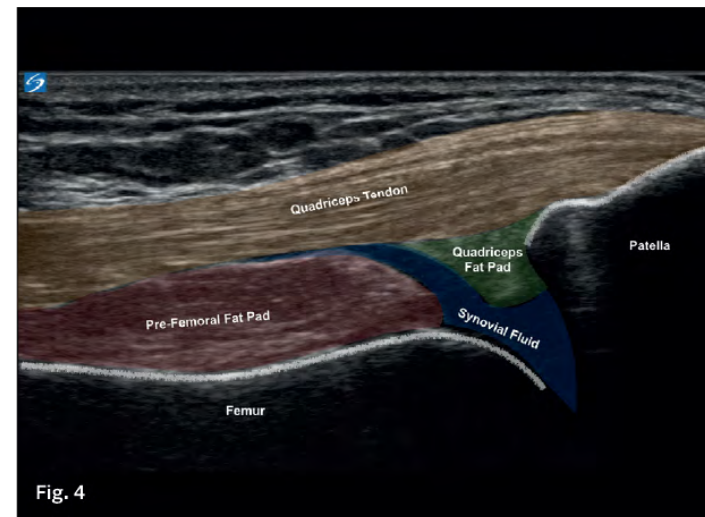


Fig. 4

Any patient. Anywhere. Anytime.

This Quick Guide is intended for healthcare professionals and not for patients or consumers. The information in this Quick Guide is provided for general educational purposes, as a convenient quick reference and a supplement to professional experience, education and training, and should not be considered the exclusive source for this type of information. This Quick Guide does not replace or supersede device labeling, including instructions for use, which accompanies any FUJIFILM Sonosite product. At all times, it is the professional responsibility of the practitioner to exercise independent clinical judgment in each particular situation. FUJIFILM Sonosite assumes no responsibility or liability for any misuse of this Quick Guide. SONOSITE and the SONOSITE logo are trademarks and registered trademarks of FUJIFILM Sonosite, Inc. in various jurisdictions. FUJIFILM is a trademark and registered trademark of FUJIFILM Corporation in various jurisdictions. All other trademarks are the property of their respective owners.

SUPRAPATELLAR RECESS

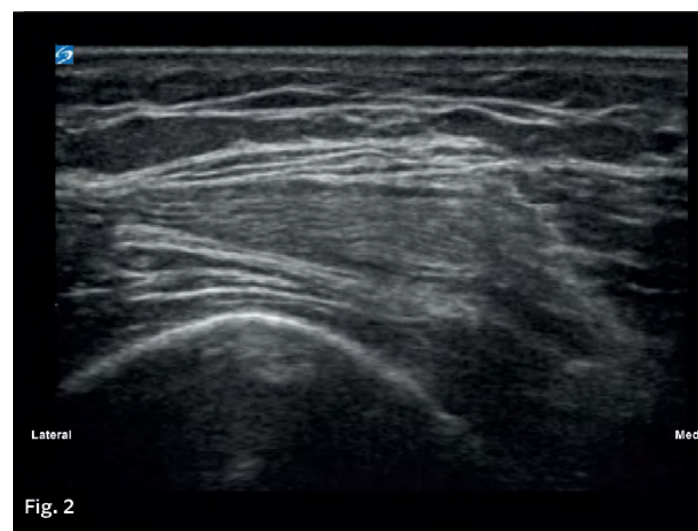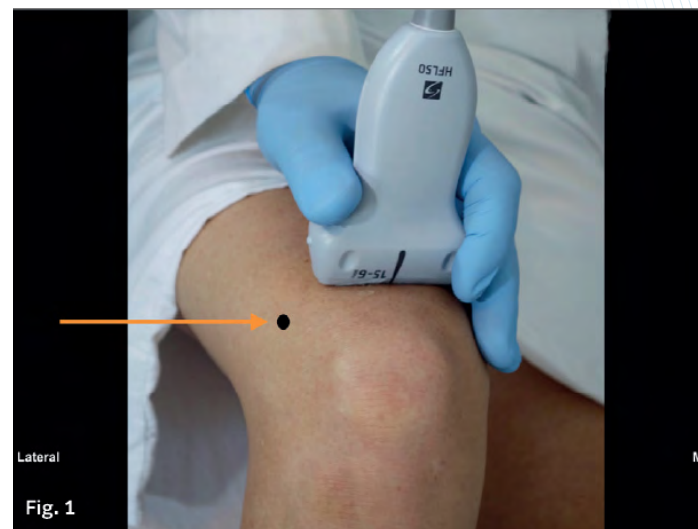
Needle injection: Transverse approach

Objective:

Use ultrasound-guidance for the aspiration of fluid and injection of medication into the suprapatellar recess of the knee joint.

The in-plane technique with a lateral-to-medial approach is the preferred method for virtually painless knee joint aspirations and injections when performed with ultrasound-guidance.

The knee joint has several compartments. All of them are contiguous in most people, so a substance injected into any one of them will distribute into the entire joint. The easiest compartment to access is the lateral suprapatellar recess, which is often called the suprapatellar "bursa." This pouch in the knee joint is the preferred target for most aspirations and injections, because it is quite superficial and thus easy to locate by ultrasound. There are no vital structures nearby that can be damaged, and this approach causes the patient less procedural discomfort than other approaches.



Any patient. Anywhere. Anytime.

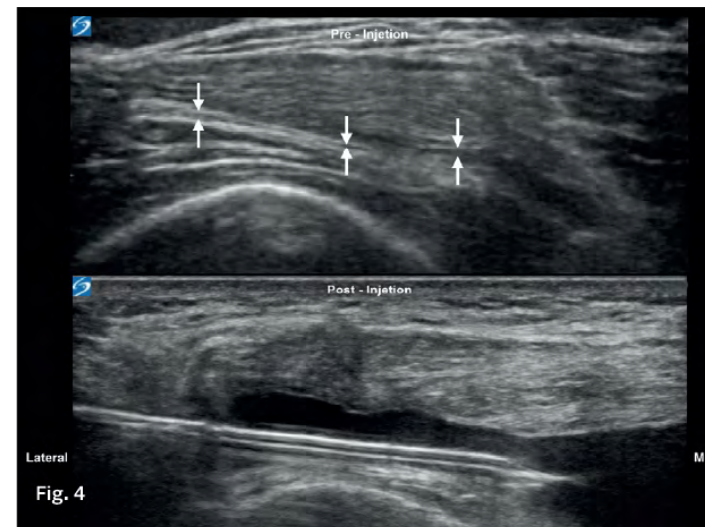
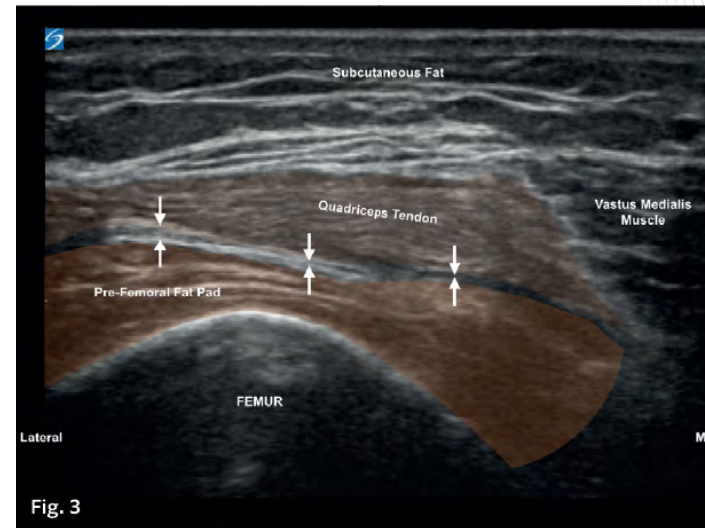
This Quick Guide is intended for healthcare professionals and not for patients or consumers. The information in this Quick Guide is provided for general educational purposes, as a convenient quick reference and a supplement to professional experience, education and training, and should not be considered the exclusive source for this type of information. This Quick Guide does not replace or supersede device labeling, including instructions for use, which accompanies any FUJIFILM Sonosite product. At all times, it is the professional responsibility of the practitioner to exercise independent clinical judgment in each particular situation. FUJIFILM Sonosite assumes no responsibility or liability for any misuse of this Quick Guide. SONOSITE and the SONOSITE logo are trademarks and registered trademarks of FUJIFILM Sonosite, Inc. in various jurisdictions. FUJIFILM is a trademark and registered trademark of FUJIFILM Corporation in various jurisdictions. All other trademarks are the property of their respective owners.

Suprapatellar recess needle injection: Transverse approach

While scanning, you can help identify the suprapatellar recess by using a finger to push on the skin on the medial and lateral sides of the joint. This will move the fat pad. However, the quadriceps tendon is anchored by four large muscles, and it will not move. Aim your needle at the interface between what moves and what does not.

Clinical Pearls:

- Patient Positioning: Place the patient in a supine position with the knee slightly bent. (Fig. 1)
 - Transducer: Use a high frequency linear transducer and the MSK exam type setting at a depth of 2-3 cm.
 - Transducer Position: Place the transducer in a transverse plane over the distal thigh about 1-2 in proximal to the patella to obtain the transverse image of the suprapatellar recess. (Fig. 2)
 - Note that the target for your needle tip is the joint space, which is about 2 cm deep and situated at the interface of the superficial surface of the prefemoral fat pad and the deep fascia of the quadriceps tendon. This is identified between the heads of the arrows in Fig. 3.
 - A needle length sufficient to reach the joint space is all that is needed. Measure the distance by pressing “freeze” on your ultrasound system, and using the caliper tools.
 - Mark the skin with pen on the lateral aspect of the leg 2 cm below the level of the transducer surface.
 - Use a sterile technique, and anesthetize the skin over your marked area.
 - Introduce the injection needle parallel to the transducer, and travel lateral-to-medial to the joint space. Fluid in the knee joint will appear as an anechoic or hypoechoic area, and the needle can be seen easily in its long axis. (Fig. 4)
 - Aspirate fluid from joint and inject medication. If possible, leave the aspiration needle in place, and switch syringes to avoid multiple passes.
- * There are no important structures in the needle path that might be injured.



Any patient. Anywhere. Anytime.

This Quick Guide is intended for healthcare professionals and not for patients or consumers. The information in this Quick Guide is provided for general educational purposes, as a convenient quick reference and a supplement to professional experience, education and training, and should not be considered the exclusive source for this type of information. This Quick Guide does not replace or supersede device labeling, including instructions for use, which accompanies any FUJIFILM Sonosite product. At all times, it is the professional responsibility of the practitioner to exercise independent clinical judgment in each particular situation. FUJIFILM Sonosite assumes no responsibility or liability for any misuse of this Quick Guide. SONOSITE and the SONOSITE logo are trademarks and registered trademarks of FUJIFILM Sonosite, Inc. in various jurisdictions. FUJIFILM is a trademark and registered trademark of FUJIFILM Corporation in various jurisdictions. All other trademarks are the property of their respective owners.

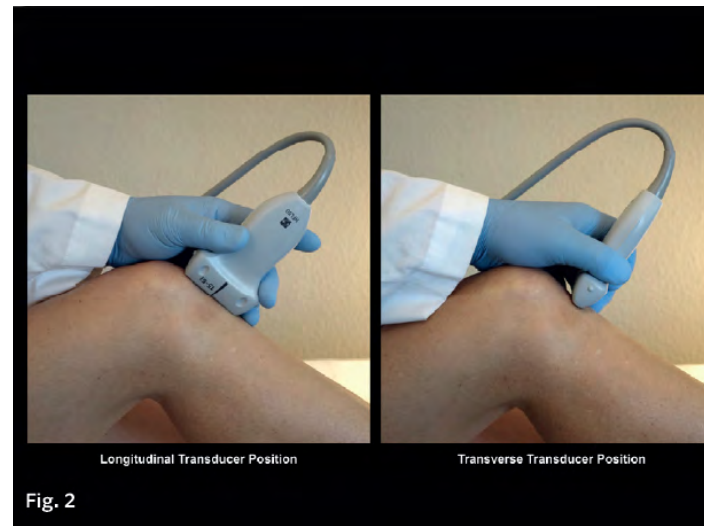
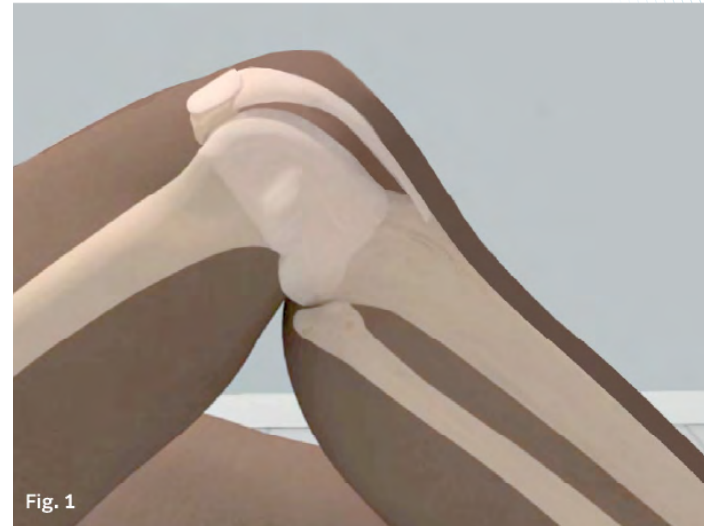INFRAPATELLAR LIGAMENT

Objective:

Image through the infrapatellar ligament in both the longitudinal and transverse planes from its origin on the distal patella to its distal insertion on the tibial tuberosity. Evaluate the region of Hoffa's fat pad, and note deep and superficial infrapatellar bursae.

The infrapatellar ligament, also known as the patellar tendon, is the continuation of the common tendon of the rectus femoris. The infrapatellar ligament connects the patella to the tibial tuberosity. The main structures in the infrapatellar region are the the pre-patellar bursa located superficial to the patella, the infrapatellar ligament, Hoffa's fat pad, and two small infrapatellar bursae located on the deep and superficial surfaces of the distal ligament, dorsal femoral condyle, and tibial tuberosity.

The infrapatellar ligament is separated from the synovial membrane of the joint by Hoffa's fat pad and two small bursae that can be seen as two small triangular hypoechoic areas. This should be regarded as normal.



Any patient. Anywhere. Anytime.

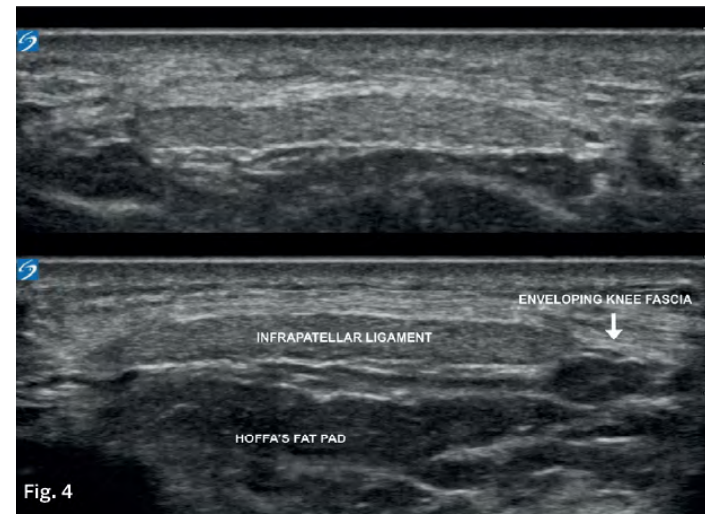
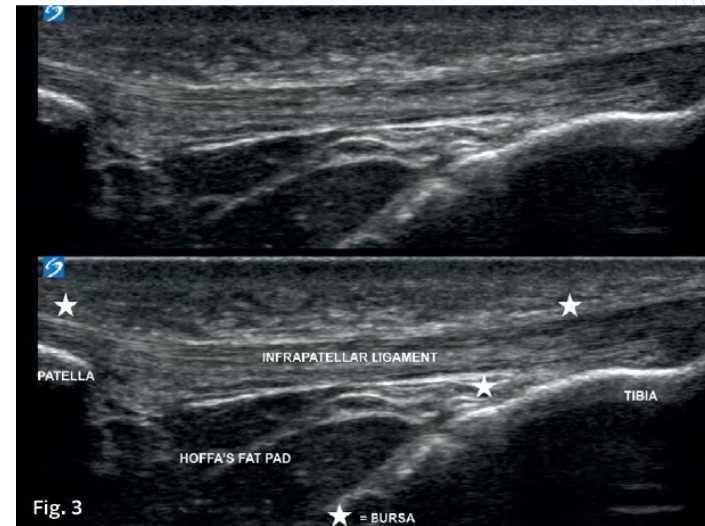
This Quick Guide is intended for healthcare professionals and not for patients or consumers. The information in this Quick Guide is provided for general educational purposes, as a convenient quick reference and a supplement to professional experience, education and training, and should not be considered the exclusive source for this type of information. This Quick Guide does not replace or supersede device labeling, including instructions for use, which accompanies any FUJIFILM Sonosite product. At all times, it is the professional responsibility of the practitioner to exercise independent clinical judgment in each particular situation. FUJIFILM Sonosite assumes no responsibility or liability for any misuse of this Quick Guide. SONOSITE and the SONOSITE logo are trademarks and registered trademarks of FUJIFILM Sonosite, Inc. in various jurisdictions. FUJIFILM is a trademark and registered trademark of FUJIFILM Corporation in various jurisdictions. All other trademarks are the property of their respective owners.

Infrapatellar ligament

Clinical Pearls:

- Patient Positioning: Position the patient with the knee slightly flexed to put some tension on the ligament. (Fig. 1)
- Transducer: Use a high frequency linear transducer and the MSK exam type at a depth of 2-3 cm.
- Transducer Position: Place the transducer in the longitudinal plane on the midline of the ligament. (Fig. 2a)
- Scan the entire width of the infrapatellar ligament from the lateral-to-medial edge, and concentrate on both the ligament and then the deeper structures of Hoffa's fat pad and bursae. (Fig. 3)
- Turn the transducer 90 degrees for a transverse scan of the infrapatellar ligament. (Fig. 2b)
- Scan the infrapatellar ligament from the origin of the patella to the distal insertion on the tibia.
- Note the enveloping fascia of the knee joint, which surrounds the entire joint and includes the medial and lateral patella-femoral ligaments. (Fig. 4)

* A color Doppler exam of Hoffa's fat pad should be performed if the patient has tenderness upon palpation.



Any patient. Anywhere. Anytime.

This Quick Guide is intended for healthcare professionals and not for patients or consumers. The information in this Quick Guide is provided for general educational purposes, as a convenient quick reference and a supplement to professional experience, education and training, and should not be considered the exclusive source for this type of information. This Quick Guide does not replace or supersede device labeling, including instructions for use, which accompanies any FUJIFILM Sonosite product. At all times, it is the professional responsibility of the practitioner to exercise independent clinical judgment in each particular situation. FUJIFILM Sonosite assumes no responsibility or liability for any misuse of this Quick Guide. SONOSITE and the SONOSITE logo are trademarks and registered trademarks of FUJIFILM Sonosite, Inc. in various jurisdictions. FUJIFILM is a trademark and registered trademark of FUJIFILM Corporation in various jurisdictions. All other trademarks are the property of their respective owners.

LATERAL COLLATERAL LIGAMENT

Objective:

Image the Lateral Collateral Ligament (LCL) from its femoral origin to the distal attachment on the posterior portion of the superior fibular head in the transverse and longitudinal planes.

The LCL of the knee originates just posterior and superior to the lateral epicondyle of the femur and inserts on the posterior portion of the superior fibular head. It often blends with the distal biceps femoris tendon, which makes it difficult, or impossible, to distinguish the LCL from the biceps femoris insertions.

Unlike the Medial Collateral Ligament (MCL) of the knee, the LCL does not adhere to the meniscus. Thus, injuries to the LCL do not necessarily affect the meniscus. The lateral inferior geniculate artery is often seen in scans of the LCL.

The LCL resists varus stress like those that occur with a medial-to-lateral force to the medial aspect of the knee, which is common with sports injuries. In addition to varus stress, the ligament stretches with full knee extension and slackens with flexion more than 30 degrees.

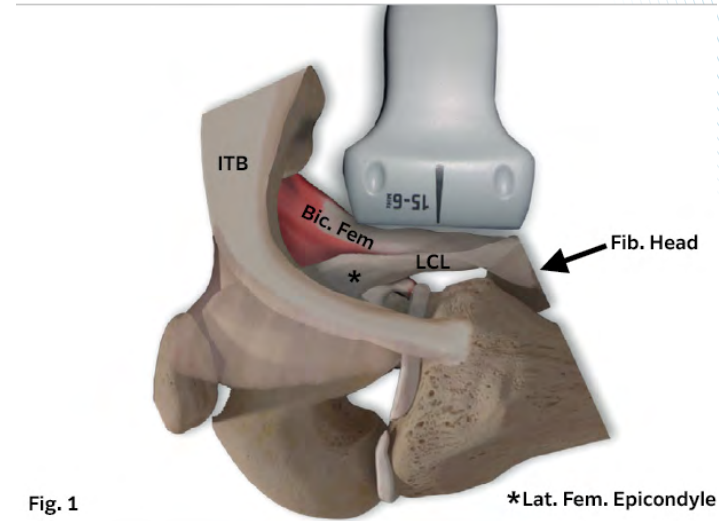


Fig. 1

*Lat. Fem. Epicondyle

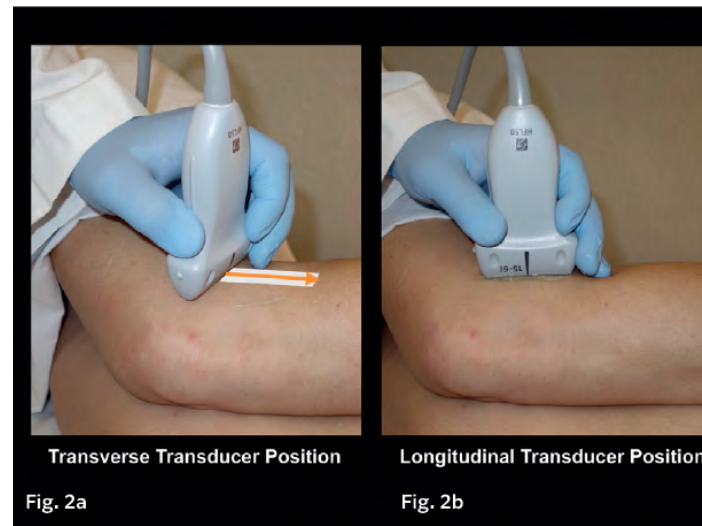


Fig. 2a

Fig. 2b

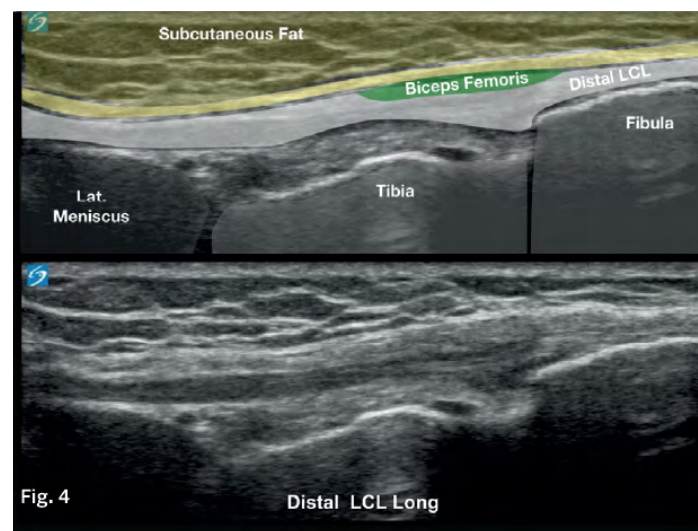
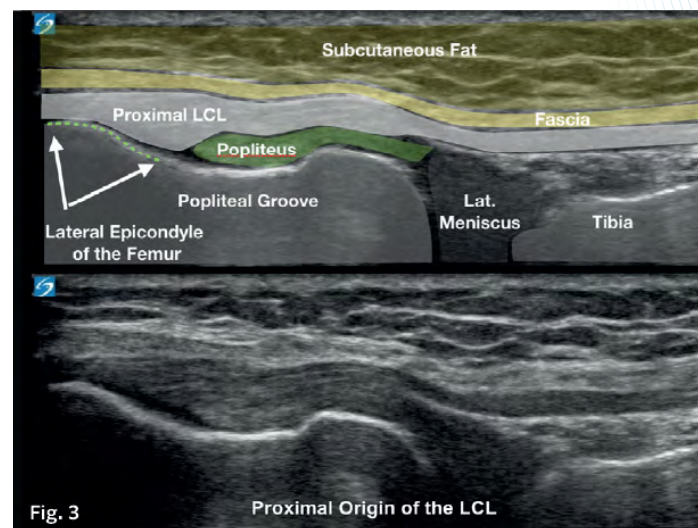
Any patient. Anywhere. Anytime.

This Quick Guide is intended for healthcare professionals and not for patients or consumers. The information in this Quick Guide is provided for general educational purposes, as a convenient quick reference and a supplement to professional experience, education and training, and should not be considered the exclusive source for this type of information. This Quick Guide does not replace or supersede device labeling, including instructions for use, which accompanies any FUJIFILM Sonosite product. At all times, it is the professional responsibility of the practitioner to exercise independent clinical judgment in each particular situation. FUJIFILM Sonosite assumes no responsibility or liability for any misuse of this Quick Guide. SONOSITE and the SONOSITE logo are trademarks and registered trademarks of FUJIFILM Sonosite, Inc. in various jurisdictions. FUJIFILM is a trademark and registered trademark of FUJIFILM Corporation in various jurisdictions. All other trademarks are the property of their respective owners.

Lateral collateral ligament

Clinical Pearls:

- Patient Positioning, Left Knee: Place the patient in the right lateral decubitus position with the left knee slightly bent about 15 degrees and the lateral aspect of the knee facing upward. (Fig. 2)
 - Transducer: Use a high frequency linear transducer and the MSK exam type setting at a depth of 2-3 cm.
 - Transducer Position: Place the transducer over the lateral epicondyle of the femur in the transverse plane perpendicular to the femur. (Fig. 2a)
 - The lateral epicondyle of the femur appears as a small bump of bone. (Fig. 3)
 - Turn the transducer 90 degrees to follow the LCL in its long axis. (Fig. 2b)
 - Keep the proximal end of the transducer immediately posterior to the epicondyle, and image the LCL in its longitudinal plane from the proximal origin on the lateral epicondyle of the femur to the distal attachment on the fibula head.
 - You should be able to see the LCL going directly superficial to the popliteus groove, across the knee joint line, and finally to the fibular head. (Fig. 3)
 - Use color power Doppler to look for hypervascularity, which is often present in the acute phases of an injury.
- * Most LCL injuries occur at its proximal end. However, the entire length of the ligament to the fibula should be scanned.



Any patient. Anywhere. Anytime.

This Quick Guide is intended for healthcare professionals and not for patients or consumers. The information in this Quick Guide is provided for general educational purposes, as a convenient quick reference and a supplement to professional experience, education and training, and should not be considered the exclusive source for this type of information. This Quick Guide does not replace or supersede device labeling, including instructions for use, which accompanies any FUJIFILM Sonosite product. At all times, it is the professional responsibility of the practitioner to exercise independent clinical judgment in each particular situation. FUJIFILM Sonosite assumes no responsibility or liability for any misuse of this Quick Guide. SONOSITE and the SONOSITE logo are trademarks and registered trademarks of FUJIFILM Sonosite, Inc. in various jurisdictions. FUJIFILM is a trademark and registered trademark of FUJIFILM Corporation in various jurisdictions. All other trademarks are the property of their respective owners.

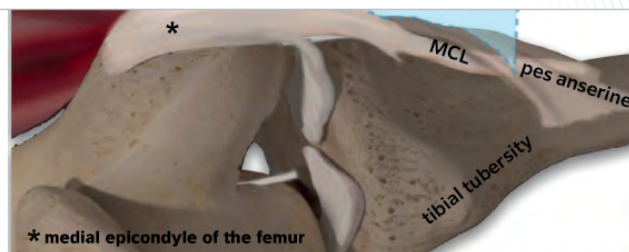
PES ANSERINE

Objective:

Image the pes anserine complex in both the longitudinal and transverse ultrasound views of the medial anterior aspect of the proximal tibia to assess for injury, tears, inflammation, or fluid collections. The distal aspect of the Medial Collateral Ligament (MCL) should also be examined as it passes just deep to the pes anserine tendons.

The pes anserine, otherwise known as the “goose foot,” is the insertion point of three major muscle tendons that join together to insert on the proximal anterior medial surface of the tibial bone at the level of the tibial neck. The three muscles are the sartorius, gracilis, and semitendinosus. The MCL of the knee travels directly beneath the tendons of the pes anserine and should be assessed for abnormalities at the same time, since they both may cause pain to the medial aspect of the knee.

The pes anserine bursa is a small, fluid-filled sac located deep to the pes anserine tendons and may cause swelling, inflammation, and knee pain. The knee may be palpated for pain and swelling at the level of the tibial tubercle distal to the knee joint. Aspiration and injections of the pes anserine with corticosteroids or other medication may be performed with increased accuracy using ultrasound-guidance for needle tip placement.



* medial epicondyle of the femur

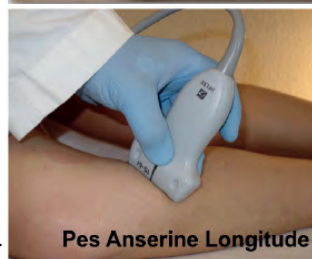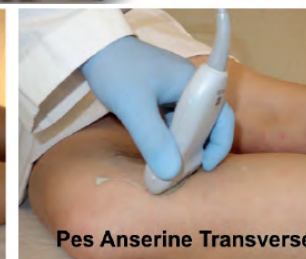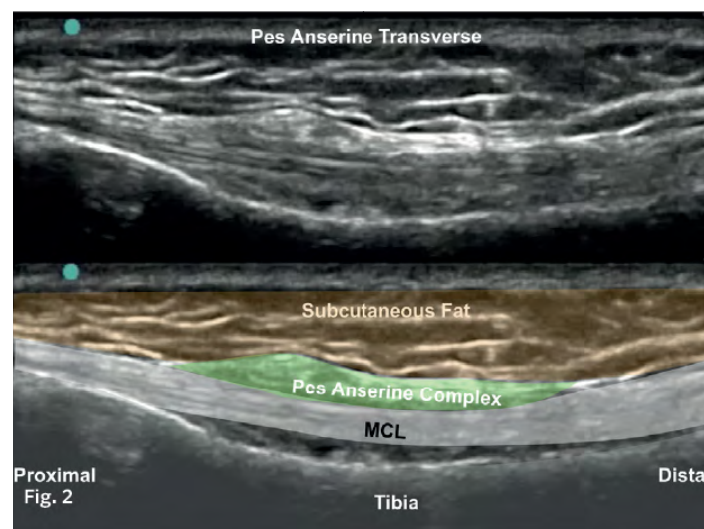


Fig. 1

Pes Anserine Longitude



Pes Anserine Transverse



Proximal
Fig. 2

Subcutaneous Fat

Pes Anserine Complex

MCL

Tibia

Distal

Any patient. Anywhere. Anytime.

This Quick Guide is intended for healthcare professionals and not for patients or consumers. The information in this Quick Guide is provided for general educational purposes, as a convenient quick reference and a supplement to professional experience, education and training, and should not be considered the exclusive source for this type of information. This Quick Guide does not replace or supersede device labeling, including instructions for use, which accompanies any FUJIFILM Sonosite product. At all times, it is the professional responsibility of the practitioner to exercise independent clinical judgment in each particular situation. FUJIFILM Sonosite assumes no responsibility or liability for any misuse of this Quick Guide. SONOSITE and the SONOSITE logo are trademarks and registered trademarks of FUJIFILM Sonosite, Inc. in various jurisdictions. FUJIFILM is a trademark and registered trademark of FUJIFILM Corporation in various jurisdictions. All other trademarks are the property of their respective owners.

Pes anserine

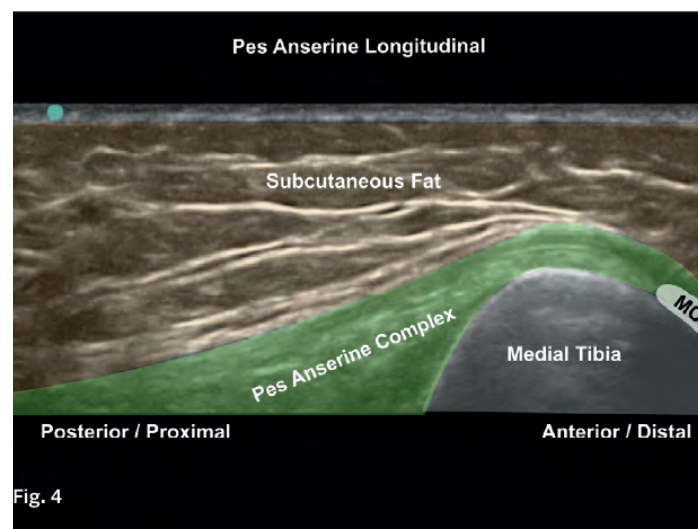
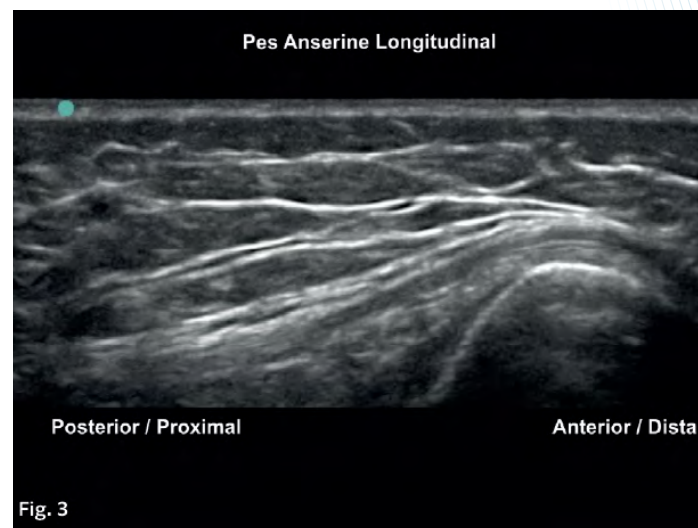
Clinical Pearls:

- Patient Positioning: Place the patient in the supine position with the leg externally rotated, or roll the patient onto their affected side with the knee flexed 20-30 degrees for access to the medial aspect of the knee. (Fig. 1)
- Transducer: Use a high frequency linear transducer and the MSK exam type setting at a depth of 2-3 cm.

Transducer Positions:

- Position A: Place the transducer on the medial aspect of the distal femur in the longitudinal position as you would for an evaluation of the MCL. Slowly slide distally over the MCL; then as you pass the knee joint, rotate the transducer slightly anterior about 10-20 degrees to image the tendons of the pes anserine complex in the short axis. (Fig. 2)
 - The three tendons of the pes anserine will appear as small, hypoechoic areas above the longitudinal view of the MCL. (Fig. 3 and Fig. 4)
 - Turn the transducer about 90 degrees for the long axis view of the pes anserine complex. In the

longitudinal view, the three muscle tendons of the pes anserine will blend together as they cross over the medial tibia. In this position, the MCL will appear in its short axis just below the distal insertion point of the pes anserine. (Fig. 3 and Fig. 4)



Any patient. Anywhere. Anytime.

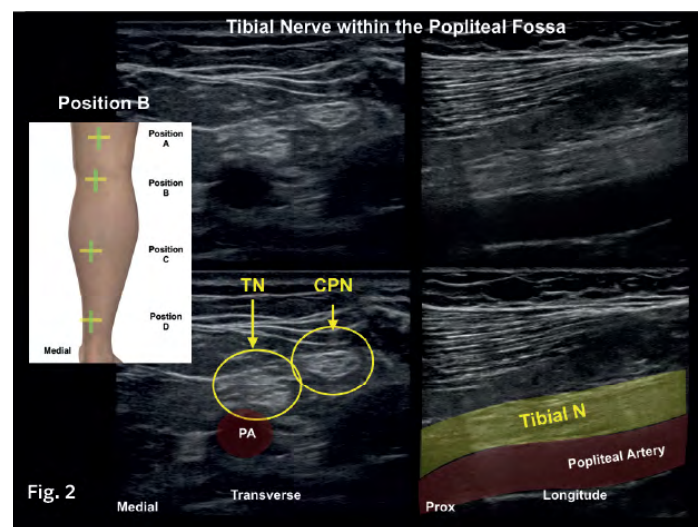
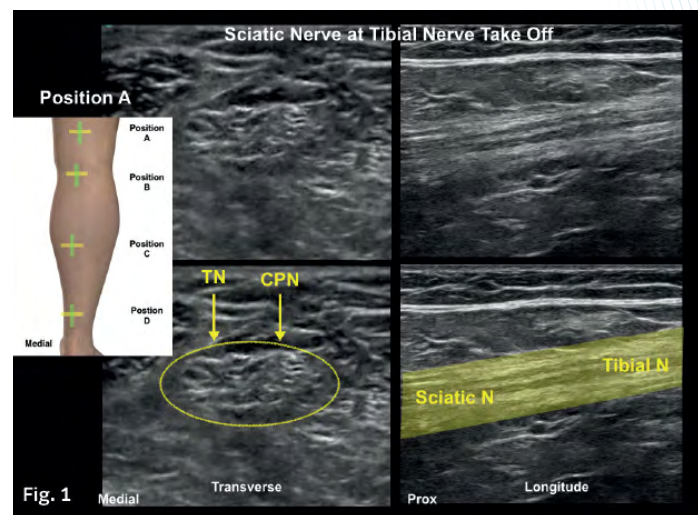
This Quick Guide is intended for healthcare professionals and not for patients or consumers. The information in this Quick Guide is provided for general educational purposes, as a convenient quick reference and a supplement to professional experience, education and training, and should not be considered the exclusive source for this type of information. This Quick Guide does not replace or supersede device labeling, including instructions for use, which accompanies any FUJIFILM Sonosite product. At all times, it is the professional responsibility of the practitioner to exercise independent clinical judgment in each particular situation. FUJIFILM Sonosite assumes no responsibility or liability for any misuse of this Quick Guide. SONOSITE and the SONOSITE logo are trademarks and registered trademarks of FUJIFILM Sonosite, Inc. in various jurisdictions. FUJIFILM is a trademark and registered trademark of FUJIFILM Corporation in various jurisdictions. All other trademarks are the property of their respective owners.

TIBIAL NERVE

Objective:

Image the Tibial Nerve (TN) for signs of blunt trauma, tears, compression, and inflammation.

The TN is an extension of the Sciatic Nerve (SN) after the bifurcation of the SN into the tibial and Common Peroneal Nerves (CPN) within the popliteal fossa of the posterior thigh. At the bifurcation of the SN into the CPN and TN, the CPN travels superficially and laterally, while the TN remains medial and deep, which provides innervation to the posterior compartment muscles of the leg.



Any patient. Anywhere. Anytime.

This Quick Guide is intended for healthcare professionals and not for patients or consumers. The information in this Quick Guide is provided for general educational purposes, as a convenient quick reference and a supplement to professional experience, education and training, and should not be considered the exclusive source for this type of information. This Quick Guide does not replace or supersede device labeling, including instructions for use, which accompanies any FUJIFILM Sonosite product. At all times, it is the professional responsibility of the practitioner to exercise independent clinical judgment in each particular situation. FUJIFILM Sonosite assumes no responsibility or liability for any misuse of this Quick Guide. SONOSITE and the SONOSITE logo are trademarks and registered trademarks of FUJIFILM Sonosite, Inc. in various jurisdictions. FUJIFILM is a trademark and registered trademark of FUJIFILM Corporation in various jurisdictions. All other trademarks are the property of their respective owners.

Tibial nerve

The Tibial Nerve (TN) provides innervation to both the deep and superficial muscle compartments of the posterior leg.

Deep Muscle Compartment:

- Popliteus
- Flexor Hallucis Longus (FHL)
- Flexor Digitorum Longus (FDL)
- Tibialis Posterior (TP)

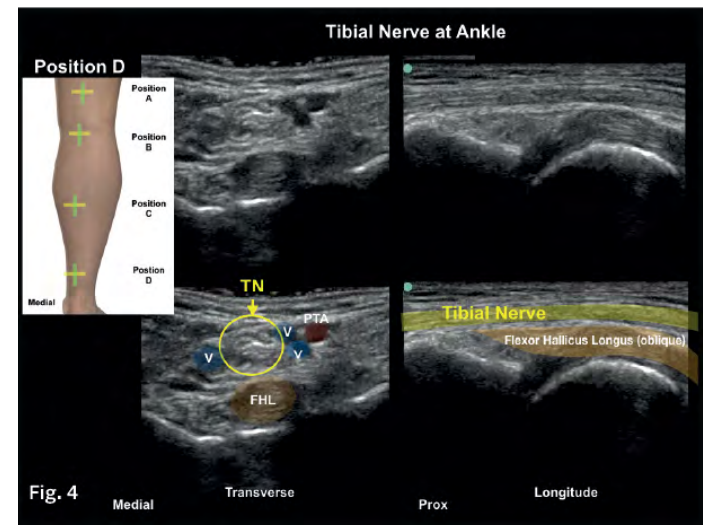
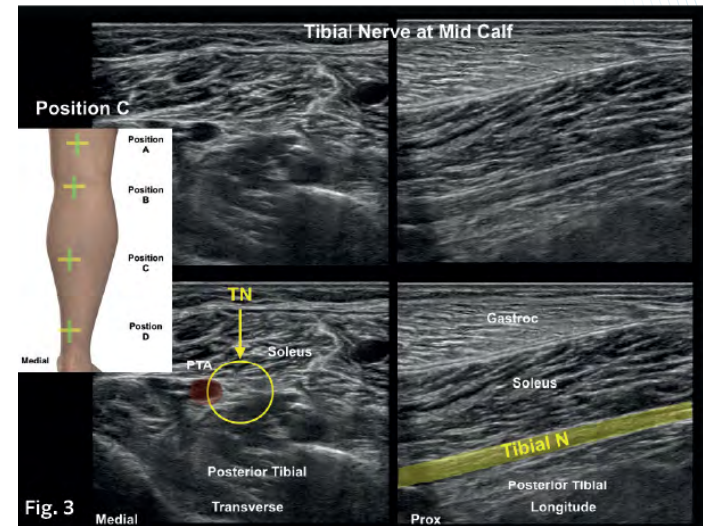
Superficial Muscle Compartment:

- Plantaris
- Soleus
- Gastrocnemius

Clinical Pearls:

- Patient Positioning: Place the patient in the prone position.
- Transducer: Use a high frequency linear transducer and the MSK exam type setting at a depth of 2- 4 cm. In some cases, a lower frequency linear transducer may need to be used due to increased patient size.
- Transducer Position: There are four positions along the back of the leg for imaging the TN. Follow the TN down the back of the leg in the transverse plane, and pause to obtain and image a longitudinal view for each transducer position.

- Position A: Place the transducer approximately 5 cm proximal to the popliteal fossa of the knee. At this level, the Sciatic Nerve (SN) bifurcates into the TN more medially and the Common Peroneal Nerves (CPN) laterally. The TN runs between the hamstring muscles and lies immediately superficial to the posterior tibial vein. (Fig. 1)
- Position B: Slide the transducer distally to the back crease of the knee. Here, the TN will stay deeper and more medial. (Fig. 2)
- Position C: Move the transducer to the mid-calf where the TN runs deep to the soleus on the medial aspect of the posterior leg. It runs along the anterior surface of the tibialis posterior muscle immediately adjacent to the posterior tibial veins and artery. (Fig. 3)
- Position D: The TN travels posteriorly to the tibia down to the ankle where it passes posteriorly and inferiorly to the medial malleolus just above the FHL tendon. (Fig. 4)



Any patient. Anywhere. Anytime.

This Quick Guide is intended for healthcare professionals and not for patients or consumers. The information in this Quick Guide is provided for general educational purposes, as a convenient quick reference and a supplement to professional experience, education and training, and should not be considered the exclusive source for this type of information. This Quick Guide does not replace or supersede device labeling, including instructions for use, which accompanies any FUJIFILM Sonosite product. At all times, it is the professional responsibility of the practitioner to exercise independent clinical judgment in each particular situation. FUJIFILM Sonosite assumes no responsibility or liability for any misuse of this Quick Guide. SONOSITE and the SONOSITE logo are trademarks and registered trademarks of FUJIFILM Sonosite, Inc. in various jurisdictions. FUJIFILM is a trademark and registered trademark of FUJIFILM Corporation in various jurisdictions. All other trademarks are the property of their respective owners.

Any patient. Anywhere. Anytime.

FUJIFILM Sonosite, Inc.

Worldwide Headquarters

21919 30th Drive SE, Bothell, WA 98021-3904

Tel: +1 (425) 951 1200 or +1 (877) 657 8050

Fax: +1 (425) 951 6800

sonosite.com

SONOSITE and the SONOSITE logo are trademarks and registered trademarks of FUJIFILM SonoSite, Inc. in various jurisdictions. FUJIFILM is a trademark and registered trademark of FUJIFILM Corporation in various jurisdictions. All other trademarks are the property of their respective owners. Information contained in this document is meant for quick reference and a supplement to formal experience, education and training. Fujifilm SonoSite would like to thank Dr. Daniel G. Malone, MD, RMSK, FACR for his contributions to this program.

Copyright © 2025 FUJIFILM Sonosite, Inc. All rights reserved. Subject to change.

EDU20856 Rev B 01/25